

A Tribute to Sven-Ivar Seldinger

T. Doby¹

It is almost impossible to imagine life without things we grew up with, so it is a little hard for us to feel the thrill of angiographers when they first heard about the Seldinger technique [1]. Present-day radiologists cannot even guess how angiography could have been done without it. We are so used to this method that we have begun dropping the eponym, as it has become the "natural" way to insert the catheter in a blood vessel. But let us recount the circumstances under which the technique was conceived.

Catheterization of the right atrium and ventricle and the pulmonary artery began to be practiced in the 1940s on the basis of the extensive experience of Cournand and Richards [2]. Arteriography at that time was accepted with some reluctance. Peripheral arteries such as the femoral and carotid, easy to reach, were injected through needles. The aorta and its branches were visualized by direct needle stick, as described by Dos Santos et al. [3] in 1931. The finer details of the visceral arteries, the thoracic and ascending aorta, and the aortic arch were still beyond reach. Efforts to extend that reach with a catheter instead of a needle were few [4].

In 1940, the Cuban radiologist Fariñas introduced catheters into the aorta through a trocar placed in the surgically exposed femoral artery. When Fariñas presented his findings at the annual meeting of the American Roentgen Ray Society in Boston in 1941, amid widespread praise, Dr. Sidney Burwell commented, "I cannot persuade myself that the incision of the femoral artery and the introduction of a catheter is a small procedure or one without hazard" [5]. Although the Society awarded Fariñas its coveted Gold Medal the following year, the medical profession was reluctant to use his method. Fariñas himself abandoned this approach; in a paper published in 1946, he blamed "the difficulty due to war conditions in obtaining rubber catheters" [6].

World War II created great difficulties, but surgical advances were made (e.g., management of patent ductus arteriosus, coarctation of the aorta) which demanded corresponding technical advances from radiology. Radiologists in Sweden, one of the few corners of the medically advanced world that escaped the ravages of war, were able to pursue questions of how to opacify the ascending aorta and aortic arch. In the late 1940s, Radner [7] in Lund thought it would be practical to opacify the ascending aorta through a catheter introduced via the radial artery. It might then be advanced into the brachial and subclavian arteries and finally into the arch. But this still involved cutting into an artery, with the concomitant risk of thrombosis or scarring and thus narrowing the lumen [8].

In the United States, Freeman and Miller [9] injected contrast material through a needle inserted in the common carotid artery, but still under direct vision and surgical cut-down. Jönsson [8] in Stockholm used a somewhat similar approach, but added a new element to the procedure: He introduced coaxial needles into the common carotid, directing them downward. After the inner, thinner needle was removed, a silver thread was inserted into the outer cannula, which had a blunt

Just over 30 years ago, Sven-Ivar Seldinger described a simple method of introducing a catheter percutaneously, which has revolutionized radiology. The *AJR* is privileged to note this anniversary while Dr. Seldinger is still actively practicing in a small city north of Stockholm.

Melvin M. Figley
Editor

Received January 28, 1983; accepted after revision July 13, 1983.

¹ Department of Radiology, Mercy Hospital, Portland, ME 04101. Address reprint requests to 22 Cottage Lane, Cape Elizabeth, ME 04107.

AJR 142:1-3, January 1984
0361-803X/84/1421-0001
© American Roentgen Ray Society

end. The silver thread was pushed carefully forward, past the carotid and innominate arteries and into the aorta. In Jönsson's description, "Using the thread as a guide the cannula is then pushed down so far that its tip comes inside the aortic arch. When a guide of this kind is used there is no risk of injury to the arterial wall. The thread is very soft and has a rounded tip and cannot do any damage if it is pushed slowly and gently" [8]. Injection took place after withdrawal of the silver thread. Despite assurances of safety, the method was not without danger and failed to gain popularity.

In 1951, 10 years after Fariñas, Peirce [12] in the United States returned to the femoral artery, but this time he inserted a polyethylene tube through a needle percutaneously. Others continued to resort to surgical cutdown, whether of the femoral artery [10] or a branch of the profunda femoris [11]. Peirce's percutaneous method was innovative but far from ideal, because the tube was not radiopaque and the end of it was rigid and could not be directed [12]. Adventurous researchers attempted to overcome these difficulties: Euler [13] in Germany injected the aortic arch through the esophagus, using an esophagoscope; in Cuba, Ponsdomenech and Beato-Nuñez [14] introduced contrast material directly into the right and left ventricles by percutaneous puncture. They reported 56 cases without fatality [14], but the method—not surprisingly—did not become popular.

This was the state of affairs in the early 1950s. Many sensed the great potential of angiography, but a method to avoid surgical placement of suitable catheters was lacking. Then an enterprising young radiologist at the Karolinska Institute in Stockholm—inspired perhaps by the one-year surgical residency that is a part of the Swedish radiology training program—came up with the solution.

Dr. Seldinger thought he could fit a needle into the end of a catheter through a side hole, thus introducing the catheter and removing the needle afterward. But because "the catheter often was not rigid enough to be advanced further into the vessel without support, [he] added to the equipment a guide wire essentially of the same type that is still in common use" (Seldinger SI, personal communication, 1976). However, the possible risks of retention of the metal tip of the wire or rupture of the catheter at the side hole were dangers that could not be disregarded. Then, "once after an unsuccessful attempt of using that technique," as he recounts, "I stood in the lab quite sad with the three items in my hand: the needle, the guide wire and the catheter; and suddenly I was aware of how they should be properly used (fig. 1). So if you put it that way, the time consumed for the invention was approximately one second" (Seldinger SI, personal communication, 1976).

The solution seems simple now: A needle is introduced, a guide wire is pushed into it, and the needle is removed. The catheter then is guided in over the wire, which also is removed [1]. The procedure was developed further in Sweden and adopted immediately in the United States, Europe, and Japan. Within a few years, the vascular supply of the abdominal organs was mapped out by Seldinger [15, 16] and others, mainly Ödman [17], also of Stockholm. Initially, to visualize the nonopaque catheter, Seldinger filled it with diodrast. A little later (1956), Ödman arranged for the production of

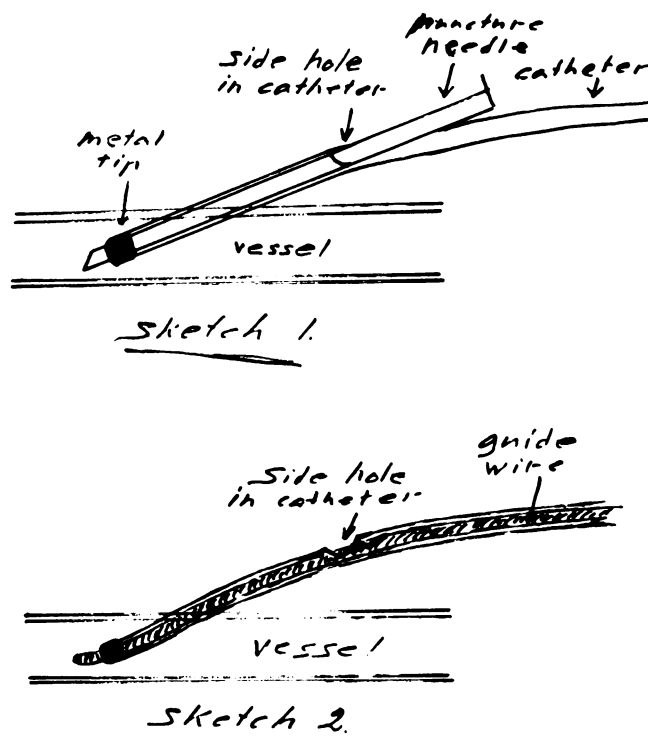


Fig. 1.—Seldinger's line drawing of two stages in development of his method of introducing catheter into artery. (Reproduced from letter to T. Doby, 1976.)

radiopaque catheters by a company. In his model experiments with cadavers, Seldinger already used catheters molded into the required shape—many of them having the same curvature as those used today. At that time there were no cassette changers; he used a wooden tunnel to hold three cassettes, which were hand-pulled after each exposure. There was no television, no image amplification, and no angiography table.

The success of his first great scientific achievement led Seldinger to explore other areas of diagnostic and interventional radiology. He described catheterization of the spleen and liver [18], and published pressure readings in the portal vein in pathologic conditions and after administration of various chemical compounds [19, 20]. He pioneered percutaneous transhepatic cholangiography [21] and wrote on pancreatic diagnostics [22], vascular anomalies in the extremities [23], and other topics. But despite the importance of these later investigations, his very first article on catheter placement was the one that opened a whole new chapter in medicine.

In 1956, the coveted Nobel Prize was awarded to Courmand, Forssmann, and Richards "for their discoveries concerning heart catheterization and pathological changes in the circulatory system" [24]. Cardiovascular catheterization had finally been accepted by the medical profession and the public. This method, especially in the arterial side of the circulation, was developed to its full extent only by the Seldinger technique [1], which enabled hundreds of investigators to achieve surprisingly successful results in diagnostics and therapy [25]. But 30 years ago, to quote the man whose discovery made such advancements possible, "nobody at that stage

could dream about the multitude of applications it should lead to" (Seldinger SI, personal communication, 1976).

REFERENCES

1. Seldinger SI. Catheter replacement of the needle in percutaneous arteriography (a new technique). *Acta Radiol* (Stockh) **1953**;39:368-376
2. Cournand A. Cardiac catheterization. *Acta Med Scand [Suppl]* **1975**;579:1-35
3. Dos Santos R, Lamas AC, Caldas JP. *Artériographie des membres et de l'aorte abdominale*. Paris: Masson et Cie, **1931**
4. Cunningham JJ, Thurber B. The abdominal aortogram: an historic perspective. *AJR* **1972**;116:441-444
5. Fariñas PL. A new technique for the arteriographic examination of the abdominal aorta and its branches. *AJR* **1941**;46:641-645
6. Fariñas PL. Retrograde abdominal aortography. *Radiology* **1946**;47:344-348
7. Radner S. Thoracic aortography by catheterization. *Acta Radiol* (Stockh) **1948**;29:179-180
8. Jönsson G. Thoracic aortography by means of a cannula. *Acta Radiol* (Stockh) **1949**;31:376-386
9. Freeman NE, Miller ER. Retrograde arteriography in diagnosis of cardiovascular lesions. *Ann Intern Med* **1949**;30:330
10. Helmsworth JA, McGuire J, Felson B. Arteriography of the aorta and its branches by means of the polyethylene catheter. *AJR* **1950**;64:196-213
11. Goodwin WE, Scardino PL, Scott WW. Translumbar aortic puncture and retrograde catheterization of the aorta. *Ann Surg* **1950**;132:944-958
12. Peirce EC. Percutaneous femoral artery catheterization in man with special reference to aortography. *Surg Gynecol Obstet* **1951**;93:56-74
13. Euler HE. Die peroesophagale Aortenpunktion. *Arch Ohren Nasen Kehlk* **1949**;155:536-567
14. Ponsdomenech ER, Beato-Nunez V. Heart puncture in man for diodrast visualization of the ventricular chambers and great arteries. *Am Heart J* **1951**;41:643-650
15. Seldinger SI. Localization of parathyroid adenomata by arteriography. *Acta Radiol* (Stockh) **1954**;42:353-366
16. Seldinger SI. Percutaneous catheterization of the renal artery. *Acta Radiol* **1956**;45:15-20
17. Ödman P. Percutaneous selective angiography of the main branches of the aorta. *Acta Radiol* (Stockh) **1956**;45:1-14
18. Seldinger SI. A simple method of catheterization of the spleen and liver. *Acta Radiol* (Stockh) **1957**;48:93-96
19. Seldinger SI, Arner O, Hagberg S, Sundblad R. Measurement of portal pressure by percutaneous transhepatic puncture. *Acta Chir Scand* **1965**;130:206-212
20. Seldinger SI, Arner O, Hagberg S, Sundblad R. Effect of phenylalanin-lysin-vasopressin on portal pressure in man as measured by percutaneous transhepatic puncture. *Acta Chir Scand* **1965**;130:213-215
21. Seldinger SI. Percutaneous transhepatic cholangiography. *Acta Radiol [Suppl]* (Stockh) **1966**:253
22. Seldinger SI, Bergkvist A. Pancreatic reflux in operative cholangiography in relation to pre- and postoperative pancreatic affection. *Acta Chir Scand* **1957**;114:191-196
23. Seldinger SI. Arteriography of the extremities. *Postgrad Med* **1961**;29:47-54
24. Sourkes TL. *Nobel Prize winners in medicine and physiology*. London, New York, Toronto: Abélard-Schuman, **1966**
25. Doby T. *Development of angiography and cardiovascular catheterization*. Littleton, MA: John Wright-PSG, **1976**