

# Effectiveness of Ultrasound-Guided Corticosteroid Injection for the Treatment of Gluteus Medius Tendinopathy

Julie M. Labrosse<sup>1</sup>  
 Étienne Cardinal<sup>1</sup>  
 Bernard E. Leduc<sup>2</sup>  
 Jacques Duranceau<sup>3</sup>  
 Jean Rémillard<sup>4</sup>  
 Nathalie J. Bureau<sup>1</sup>  
 Assia Belblidia<sup>1</sup>  
 Paul Brassard<sup>5</sup>

**Keywords:** gluteus medius tendinopathy, greater trochanteric pain syndrome, hip joint, ultrasound guidance, ultrasound-guided corticosteroid injection

DOI:10.2214/AJR.08.1215

Received May 12, 2008; accepted after revision July 20, 2009.

<sup>1</sup>Department of Radiology, Centre Hospitalier de l'Université de Montréal (CHUM), Pavillon Saint-Luc, 1058 rue Saint-Denis, Montréal, QC, Canada H2X 3J4. Address correspondence to É. Cardinal (etienne.cardinal@gmail.com).

<sup>2</sup>Physical Medicine & Rehabilitation Division, CHUM, Montréal, QC, Canada.

<sup>3</sup>Service de Santé, Université de Montréal, Montréal, QC, Canada.

<sup>4</sup>Centre de Physiothérapie Dorchester, Montréal, QC, Canada.

<sup>5</sup>Division of Clinical Epidemiology, McGill University Health Center, Montréal, QC, Canada.

AJR 2010; 194:202–206

0361–803X/10/1941–202

© American Roentgen Ray Society

**OBJECTIVE.** The objective of our study was to evaluate the effectiveness of ultrasound-guided corticosteroid injection for the treatment of gluteus medius tendinopathy.

**SUBJECTS AND METHODS.** We prospectively evaluated 54 consecutive patients (48 women, six men; mean age, 54.7 years; mean body mass index, 26 kg/m<sup>2</sup>) with a clinical diagnosis of gluteus medius tendinopathy. Pain assessment using a 10-cm visual analog scale (VAS) was obtained as part of the initial clinical evaluation of all patients. A hip ultrasound study was performed followed by a gluteus medius peritendinous ultrasound-guided injection of 30 mg of triamcinolone combined with 3 mL of bupivacaine 0.5% using an anterior oblique coronal plane. One month after treatment, participants were reassessed clinically, and they were asked to quantify their pain using the VAS pain score and their satisfaction with the outcome of the injection using a 4-point rating scale (very satisfied, somewhat satisfied, somewhat dissatisfied, or very dissatisfied). Statistical analysis included a paired Student's *t* test (comparison of pain levels before and after treatment, *p* = 0.05) and a multivariate analysis of covariance.

**RESULTS.** There was a 55% average reduction of pain level before versus after treatment (mean VAS pain score, 6.4 vs 2.9 cm, respectively; *p* < 0.001). One month after treatment, 72% of the patients showed a clinically significant improvement in pain level, which was defined as a reduction in the VAS pain score of ≥ 30%. Seventy percent of patients were satisfied with the results of the intervention. No correlation was shown between treatment outcome and any of the clinical variables or ultrasound findings.

**CONCLUSION.** Our study shows that a peritendinous ultrasound-guided corticosteroid injection may be an effective treatment of gluteus medius tendinopathy.

**L**ateral hip pain is often referred to as “greater trochanteric pain syndrome,” which is a clinical syndrome characterized by chronic pain localized to the lateral aspect of the hip. It has traditionally been associated with trochanteric bursopathy [1–3], although the results of studies with MRI [4–7] and sonography [8] have shown that greater trochanteric pain syndrome is more often the result of gluteus medius tendinopathy. Trochanteric bursitis is less common by itself and is seen more often in association with gluteus medius tendinopathy [4, 6]. Tears and calcifications also may be associated with gluteus medius tendinopathy, sharing a similarity with the rotator cuff [6, 9]. Tendinopathy of the gluteus minimus occurs less frequently than gluteus medius tendinopathy [8].

Ultrasound is a technique that has gained widespread acceptance for musculoskeletal

imaging and guiding interventions [8, 10–16]. This noninvasive, nonionizing imaging technique allows continuous monitoring of the needle position, which facilitates the performance of safe and precise cortisone injections. To our knowledge, a specific technique for ultrasound-guided cortisone injections in the treatment of gluteus medius tendinopathy has not been reported. Therefore, the aim of our study was to describe an ultrasound-guided corticosteroid injection technique in the treatment of gluteus medius tendinopathy and to evaluate its effectiveness 1 month after treatment.

## Subjects and Methods

### Study Population

Approval from our institutional review board and informed consent from all participants were obtained. Fifty-four consecutive patients were prospectively evaluated: 48 women and six men who ranged in age from 35 to 78 years (mean, 54.7

## Ultrasound-Guided Corticosteroid Injection for Tendinopathy

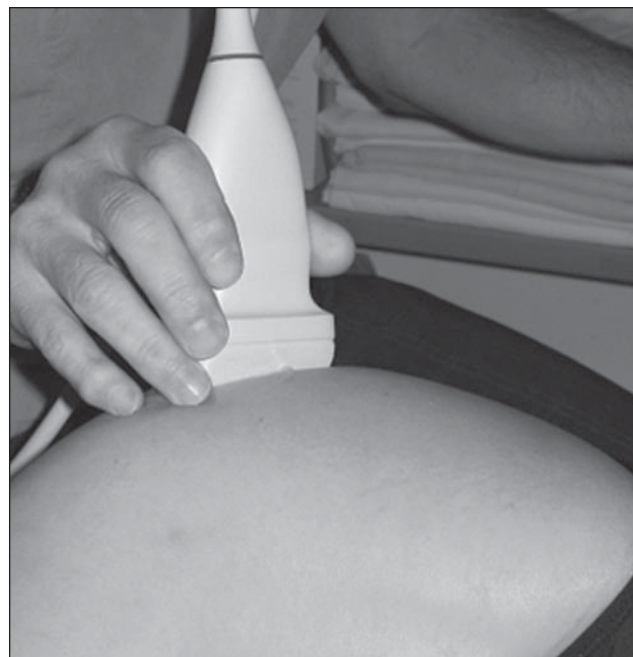years) with a body mass index that ranged from 20 to 35.5 kg/m<sup>2</sup> (mean, 26 kg/m<sup>2</sup>). All patients had a confirmed clinical diagnosis of medial gluteus tendinopathy established by a physician who specializes in physical medicine and rehabilitation. The clinical criteria for the diagnosis of gluteus medius tendinopathy included a history of trochanteric pain for at least 6 weeks, reproducibility of the pain by local pressure on the greater trochanter, aggravation of pain by resisted isometric hip abduction and by passive hip adduction, ineffectiveness of conservative treatment (i.e., analgesics, antiinflammatory medication, physiotherapy), no lumbar pathology, and pain intensity score of at least 5 on a 10-cm visual analog scale (VAS). The VAS is a standardized 10-cm scale, ranging from “no pain” to “worst-conceivable pain,” on which patients were asked to draw a line starting from the left (no pain) and to stop at the point that corresponded to the actual level of pain.

Exclusion criteria were cortisone injection in the affected hip in the previous 3 months, history of surgery in the affected hip, anticoagulation therapy or coagulation disorders, unavailability for follow-up, and incapacity to give informed consent. Recent hip radiographs (< 6 months) were evaluated by a musculoskeletal radiologist to exclude other causes of hip pain, such as fracture, avascular necrosis, and coxofemoral arthrosis or arthritis. No MRI studies were undertaken for this study.

### Ultrasound-Guided Corticosteroid Injection

An initial ultrasound assessment of the symptomatic hip was performed within 1 month of the

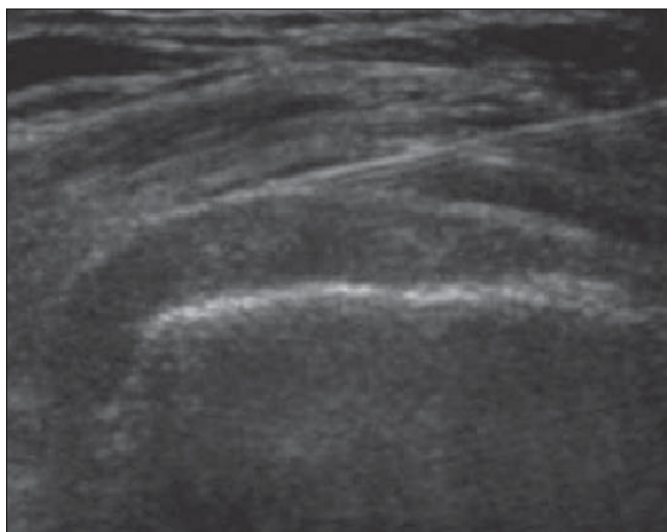
**Fig. 1**—Photograph shows position of patient for ultrasound-guided cortisone injection: lateral decubitus with symptomatic hip upward, in slight flexion. Probe should be in oblique coronal position.



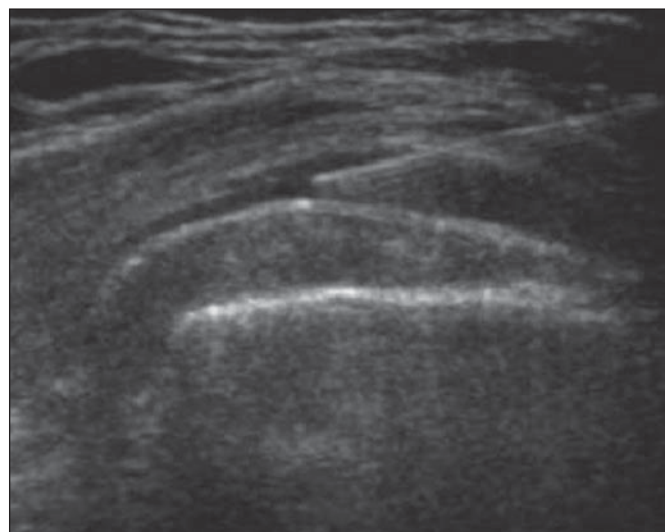
initial evaluation by a musculoskeletal radiologist with 14 years' experience using a linear 5-7- or 5-12-MHz transducer (ATL or HDI 5000, Philips Healthcare). Patients were positioned in lateral decubitus lying on the opposite side with both hips slightly flexed (Fig. 1). The anterior and lateral facets of the greater trochanter were first localized on a transverse view. The gluteus minimus tendon was examined as it attaches on the anterior facet of the greater trochanter [17]. The lateral and posterior parts of the gluteus me-

dius tendon were evaluated as they insert on the lateral and superoposterior facets of the greater trochanter, respectively.

During the diagnostic ultrasound, signs of gluteus medius and minimus tendinopathy were assessed: hypoechogenicity; loss of the fibrillary pattern; tendon thickness; and the presence of calcifications, enthesophytes, or tears. Calcifications presented as intratendinous echogenic images with or without posterior acoustic shadow. Entesophytes were documented as small echogenic



**A**



**B**

**Fig. 2**—Ultrasound-guided cortisone injection.

**A**, Tip of 22-gauge 3.5-inch spinal needle is placed at surface of distal gluteus medius tendon using anterolateral approach.

**B**, Peritendinous injection is performed.

bony projections from the greater trochanter surface within the tendon. Tears were diagnosed if a well-defined anechoic image with interruption of fibers was present in the tendon. The location of maximum pain when increased local transducer pressure was applied was also recorded. The ultrasound study also evaluated signs of trochanteric bursopathy, such as synovial thickening or fluid. The lateral and anterior aspects of the hip were also scanned for any other abnormality.

To prepare the patient for the cortisone injection, local skin anesthesia was performed under sterile conditions after cutaneous aseptis. The transducer was positioned in an oblique coronal plane, and a 22-gauge spinal needle fixed to a 10-mL syringe filled with 2% lidocaine (Xylocaine, AstraZeneca) was inserted via an anterior approach. Using continuous ultrasound real-time monitoring, the operator progressively advanced the needle while intermittently injecting a small amount of lidocaine. This injection technique allowed deeper local anesthesia to be obtained and also helped to localize the tip of the needle by mobilizing surrounding tissue. The fascia lata was traversed with the needle, and its tip was positioned at the surface of the lateral part of the distal gluteus medius tendon (Fig. 2A). Approximately 1 mL of lidocaine was injected with peritendinous fluid pooling to confirm proper needle position-

ing (Fig. 2B). A peritendinous cortisone injection (30 mg of triamcinolone and 3 mL of bupivacaine 0.5%) was then performed under continuous ultrasound monitoring. After ultrasound-guided cortisone injection, patients were instructed not to take any other pain or antiinflammatory medication.

#### Posttreatment Assessment

A 1-month follow-up with a physician included a clinical reevaluation of pain status associated with the gluteus medius tendinopathy by assessing local tenderness at the trochanter level, by local pressure, by resisted isometric hip abduction, and by passive hip adduction. Patients assessed pain intensity using a VAS pain score and characterized their satisfaction with the outcome of the procedure using a 4-point patient satisfaction rating scale (very satisfied, somewhat satisfied, somewhat dissatisfied, or very dissatisfied) [18]. The patient satisfaction data were grouped as satisfied or not for analysis.

#### Statistical Analysis

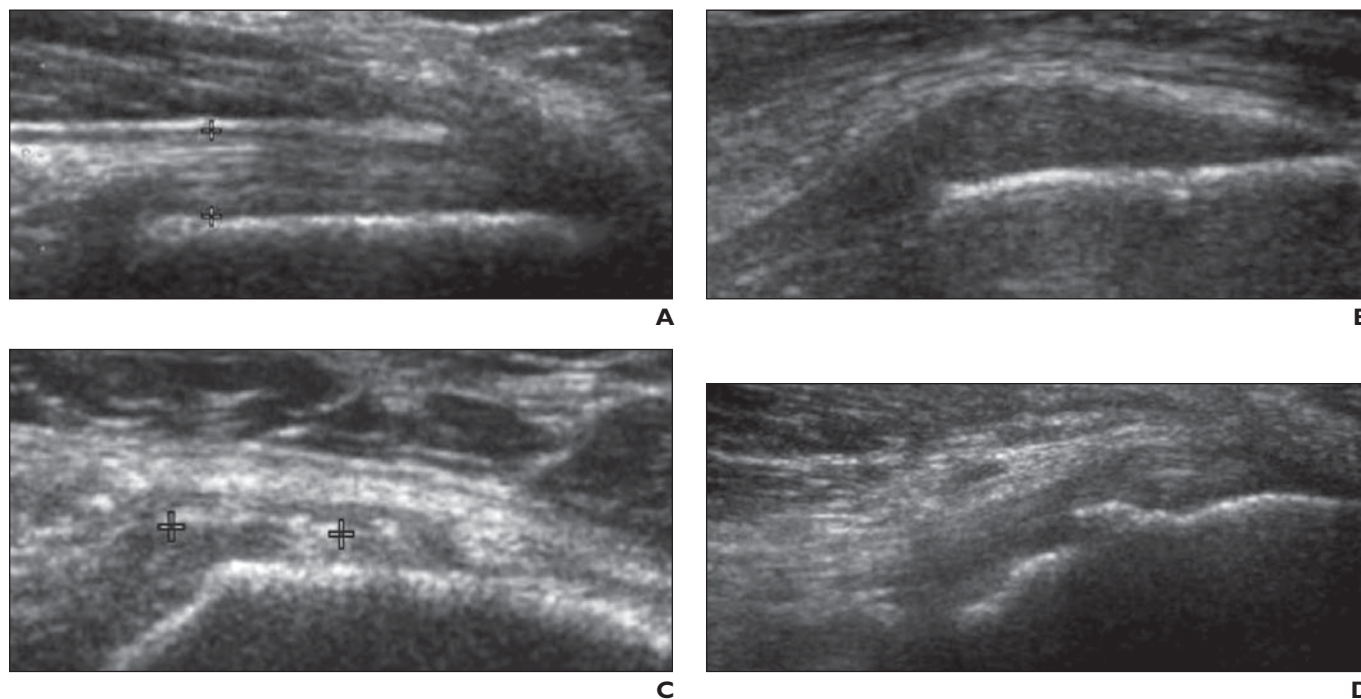
A paired Student's *t* test was used to compare pain intensity (VAS scores) before and after treatment. The analysis of covariance was used to explore potential associations between demographic and clinical characteristics and between global satisfaction with outcome and pain gradients. Sta-

tistical significance was considered at the  $p = 0.05$  level. A reduction of 30% or more of the baseline VAS score of pain level was considered clinically significant [19].

#### Results

In 72% of the patients ( $n = 39$ ), a clinically and statistically significant improvement in pain level was seen 1 month after treatment. Overall, there was a 55% average difference in the VAS scores obtained before and after intervention (mean VAS score, 6.4 vs 2.9 cm, respectively;  $p < 0.001$ ). Seventy percent of patients ( $n = 38$ ) were satisfied with the results of the intervention. There was no association between demographic or clinical variables and overall satisfaction ratings or the pain gradients. No complication has occurred.

Abnormal ultrasound findings, including those related to gluteus medius tendinopathy, were observed in all 54 participants (Fig. 3 and Table 1). The mean tendon thickness was 3.3 mm. Signs of trochanteric bursopathy were seen in 52% of the hips with tendinopathy. Most patients complained of pain reproduced when pressure was applied with the transducer on the lateral part of the tendon ( $n = 49$ ) compared with the posterior part ( $n = 4$ ) or both parts ( $n = 1$ ). There was



**Fig. 3**—Ultrasound appearances of gluteus medius tendon.

**A**, Hyperechoic fibrillary pattern of normal tendon (*cursors*) in 35-year-old woman.

**B**, Ultrasound sign of gluteus medius tendinopathy in 52-year-old woman: tendon hypoechogenicity with loss of normal fibrillary pattern.

**C**, Ultrasound sign of gluteus medius tendinopathy in 73-year-old woman: intratendinous calcifications (*cursors*).

**D**, Ultrasound sign of gluteus medius tendinopathy in 58-year-old woman: enthesophytes (i.e., cortical irregularities).

**TABLE 1: Ultrasound Findings Suggestive of Gluteus Medius Tendinopathy in Patients With Clinical Diagnosis of Greater Trochanteric Pain Syndrome**

Ultrasound Findings Suggestive of Gluteus Medius Tendinopathy	No. (%) of Patients
Hypoechoogenicity	54 (100)
Loss of fibrillary pattern	50 (93)
Enthesophytes	48 (89)
Calcifications	31 (57)
Tears	1 (2)

no association between any ultrasound signs of trochanteric tendinopathy and the overall satisfaction or pain gradients. Also, the patients with signs of bursopathy did not show a statistically different response to treatment when compared with participants with no bursal signs.

**Discussion**

Greater trochanteric pain syndrome is a common disorder that is typically unilateral and characteristically affects middle-aged to elderly women but may also be found in young, active individuals [3, 20, 21]. The underlying causes remain unclear but probably are multifactorial and involve mechanical and degenerative processes. Because the gluteus minimus and medius muscles are involved in stabilizing and externally rotating the hip, a similarity with the degenerative process of the rotator cuff has been recognized [22, 23]. The medical treatment of gluteus tendinopathy includes physiotherapy, nonsteroidal antiinflammatory medication, and local injection of corticosteroids. These peritrochanteric injections have traditionally been performed blindly in a clinical setting without the use of imaging guidance but may be difficult to perform owing to the depth of the desired injection site [2, 24]. Fluoroscopic guidance was shown to be superior (> 90%) to blinded injection (45%) for adequate intratrochanteric bursa positioning of the needle for cortisone injection [25]. To our knowledge, however, the therapeutic efficacy of fluoroscopy- or ultrasound-guided injections for greater trochanteric pain syndrome has not previously been addressed.

The use of ultrasound for guiding musculoskeletal procedures has increased over the past several years [10–15]. Advantages of ultrasound over fluoroscopy include its soft-tissue imaging capabilities that allow a diagnostic study to be performed before cortisone injection. Ultrasound also permits continu-

ous real-time monitoring of the needle position relative to the targeted distal gluteus medius tendon. Also, in contrast with fluoroscopy, which generally requires contrast injection for peritendinous or trochanteric bursa opacification, ultrasound does not expose the patient to ionizing radiation and the risks of iodine allergy.

The evaluation of ultrasound signs of gluteus medius tendinopathy has already been reported and was not the aim of our study [8]. We did, however, perform a diagnostic study before the cortisone injection and documented that all of our patients had ultrasound signs of tendinopathy, although only 52% had associated signs of trochanteric bursopathy. These results are in accordance with those of other studies showing that gluteus medius tendinopathy is the predominant finding in patients with greater trochanteric pain syndrome [3, 8] and suggest that tendinopathy is the initiating disorder and that bursopathy may or may not accompany it. Therefore, this finding emphasizes that cortisone injections need to be targeted around the distal gluteus medius tendon rather than around the greater trochanteric bursa.

The 3.3-mm mean thickness measurement of the gluteus medius tendon in our study population was lower than the 9.7-mm value reported by Connell et al. [8]. This discrepancy is explained by the fact that we measured the thinner lateral part of the gluteus medius tendon, whereas the posterior thicker part of the tendon was assessed by Connell and colleagues. Measurements obtained by Pfirrmann et al. [17] on MRI also indicated that values for the posterior portion of the tendon are higher than those for the lateral part, which they described as very thin.

The results of sonographic palpation in our study showed that the lateral part of the gluteus medius tendon was more often the site of tenderness than either the posterior portion of the gluteus medius tendon or the gluteus mini-

mus tendon. Pain relief was obtained in most of our patients by injecting corticosteroids around the lateral part of the gluteus medius tendon where it attaches on the lateral facet of the greater trochanter. Because our study was designed to evaluate the short-term effects of the treatment, we cannot speculate on the possible duration of symptom relief beyond the 1-month follow-up. The long-term prognosis could vary according to the evolution of the tendinopathy, the amount of functional use or overuse of the involved hip in the future, and the sufficiency and observance of treatments undertaken to improve the strength and range of motion of the hip.

Limitations of our study include, as with any ultrasound procedure, that the technique is dependent on sonographer experience and skill. Signs of tendinopathy may be mimicked by anisotropy of tendons, and care should be taken during ultrasound scanning to maintain the transducer surface parallel to the tendon fibers. The degree of difficulty in performing the ultrasound-guided injection can potentially be accentuated by a patient's high body mass index, which increases the attenuation and depth of the injection site. Needle visualization decreases because of the steeper angle that is required for a deeper injection. Also, the greater probe compression that is needed to image a deeply located gluteus medius tendon can lead to underestimation of associated bursitis by expressing the fluid out of the imaged area. However, obese patients are a challenge also for blind-injection by the clinician.

Another limitation of the study is the absence of an ultimate reference standard that can be used for the diagnosis of gluteus tendinopathy; however, we carefully selected the study patients on the basis of a clinical evaluation completed by an experienced physical medicine and rehabilitation physician using strict criteria. The favorable response of patients to ultrasound-guided injection that was achieved in our study tends to confirm the correct diagnosis of gluteus medius tendinopathy. Patients not reporting a satisfactory pain improvement after cortisone injection may have had an inaccurate clinical diagnosis despite the presence of ultrasound signs of tendinosis. Our study population is too small to draw conclusions about specific characteristics that may differentiate patients who responded well from those who did not.

Our study was not randomized and controlled. Randomized trials are needed to clarify the level of scientific evidence in favor of

this approach. However, in a routine clinical setting, a specific indication for ultrasound-guided injection might be for the treatment of patients who did not respond initially to a blinded cortisone injection. Finally, a clinical follow-up over a period of time exceeding 1 month would allow assessment of the long-term efficacy of this treatment.

In conclusion, our study showed that a peritendinous ultrasound-guided corticosteroid injection may be an effective treatment for patients with greater trochanteric pain syndrome associated with gluteus medius tendinopathy.

References

1. Shbeeb MI, Matteson EL. Trochanteric bursitis (greater trochanter pain syndrome). *Mayo Clin Proc* 1996; 71:565–569
2. Ege Rasmussen KJ, Fanø N. Trochanteric bursitis: treatment by corticosteroid injection. *Scand J Rheumatol* 1985; 14:417–420
3. Walsh G, Archibald CG. MRI in greater trochanteric pain syndrome. *Australas Radiol* 2003; 47:85–87
4. Kingzett-Taylor A, Tirman PF, Feller J, et al. Tendinosis and tears of gluteus medius and minimus muscles as a cause of hip pain: MR imaging findings. *AJR* 1999; 173:1123–1126
5. Chung CB, Robertson JE, Cho GJ, Vaughan LM, Copp SN, Resnick D. Gluteus medius tendon tears and avulsive injuries in elderly women: imaging findings in six patients. *AJR* 1999; 173:351–353
6. Bird PA, Oakley SP, Shnier R, Kirkham BW. Prospective evaluation of magnetic resonance imaging and physical examination findings in patients with greater trochanteric pain syndrome. *Arthritis Rheum* 2001; 44:2138–2145
7. Dwek J, Pfirrmann C, Stanley A, Pathria M, Chung CB. MR imaging of the hip abductors: normal anatomy and commonly encountered pathology at the greater trochanter. *Magn Reson Imaging Clin N Am* 2005; 13:691–704
8. Connell DA, Bass C, Sykes CJ, Young D, Edwards E. Sonographic evaluation of gluteus medius and minimus tendinopathy. *Eur Radiol* 2003; 13:1339–1347
9. Miller TT. Abnormalities in and around the hip: MR imaging versus sonography. *Magn Reson Imaging Clin N Am* 2005; 13:799–809
10. Adler RS, Sofka CM. Percutaneous ultrasound-guided injections in the musculoskeletal system. *Ultrasound Q* 2003; 19:3–12
11. Cardinal E, Beaugard GC, Chhem RK. Interventional musculoskeletal ultrasound. *Semin Musculoskelet Radiol* 1997; 1:311–318
12. Cardinal É, Chhem RK, Beaugard GC. Ultrasound-guided interventional procedures in the musculoskeletal system. *Radiol Clin North Am* 1998; 36:597–604
13. Christensen RA, Van Sonnenberg E, Casola G, Wittich GR. Interventional ultrasound in the musculoskeletal system. *Radiol Clin North Am* 1988; 26:145–156
14. Weidner S, Kellner W, Kellner H. Interventional radiology and the musculoskeletal system. *Best Pract Res Clin Rheumatol* 2004; 18:945–956
15. Fessell DP, Jacobson JA, Craig J, et al. Using sonography to reveal and aspirate joint effusions. *AJR* 2000; 174:1353–1362
16. Gibbon WW. Interventional radiology techniques in musculoskeletal disease. *Baillieres Clin Rheumatol* 1996; 10:711–727
17. Pfirrmann CW, Chung CB, Theumann NH, Trudell DJ, Resnick D. Greater trochanter of the hip: attachment of the abductor mechanism and a complex of three bursae—MR imaging and MR bursography in cadavers and MR imaging in asymptomatic volunteers. *Radiology* 2001; 221:469–477
18. Hudak PL, Wright JG. The characteristics of patient satisfaction measures. *Spine* 2000; 25:3167–3177
19. Farrar JT, Young JP Jr, LaMoreaux L, Werth JL, Poole RM. Clinical importance of changes in chronic pain intensity measured on an 11-point numerical pain rating scale. *Pain* 2001; 94:149–158
20. Bard H, Vuillemin-Bodaghi V, Mutschler C. Tendinopathies du moyen et du petit glutéal: étude pilote de critères cliniques. *Rev Rhum Ed Fr* 2006; 73:552
21. Tortolani PJ, Carbone JJ, Quartararo LG. Greater trochanteric pain syndrome in patients referred to orthopedic spine specialists. *Spine J* 2002; 2:251–254
22. Gottschalk F, Kourosh S, Leveau B. The functional anatomy of tensor fasciae latae and gluteus medius and minimus. *J Anat* 1989; 166:179–189
23. Kagan A 2nd. Rotator cuff tears of the hip. *Clin Orthop Relat Res* 1999; 368:135–140
24. Shbeeb MI, O'Duffy JD, Michet CJ Jr, O'Fallon WM, Matteson EL. Evaluation of glucocorticosteroid injection for the treatment of trochanteric bursitis. *J Rheumatol* 1996; 23:2104–2106
25. Cohen SP, Narvaez JC, Lebovits AH, Stojanovic MP. Corticosteroid injections for trochanteric bursitis: is fluoroscopy necessary? A pilot study. *Br J Anaesth* 2005; 94:100–106

Downloaded from www.ajronline.org by MIT Libraries on 12/06/24 from IP address 18.97.14.89. Copyright ARRS. For personal use only; all rights reserved