

# Comparison of International Ovarian Tumor Analysis Simple Rules to Society of Radiologists in Ultrasound Guidelines for Detection of Malignancy in Adnexal Cysts

Krupa K. Patel-Lippmann<sup>1</sup>  
 Elizabeth A. Sadowski<sup>2,3</sup>  
 Jessica B. Robbins<sup>2</sup>  
 Viktoriya Paroder<sup>4</sup>  
 Lisa Barroilhet<sup>3</sup>  
 Elizabeth Maddox<sup>2</sup>  
 Timothy McMahon<sup>5</sup>  
 Emmanuel Sampene<sup>6</sup>  
 Ashish P. Wasnik<sup>7</sup>  
 Alexander D. Blaty<sup>8</sup>  
 Katherine E. Maturen<sup>7,9</sup>

**OBJECTIVE.** The purpose of this study was to evaluate the International Ovarian Tumor Analysis (IOTA) simple rules and the Society of Radiologists in Ultrasound (SRU) guidelines for detecting ovarian malignancy in a general population of women presenting to radiology departments with adnexal cystic lesions.

**MATERIALS AND METHODS.** A retrospective multicenter study of ultrasound-detected adnexal cystic lesions with appropriate follow-up was conducted. Lesions were classified into benign, indeterminate, or malignant categories according to criteria based on the IOTA simple rules and the SRU guidelines. The prevalence of nonneoplastic cysts, neoplasms, and malignant tumors was calculated. Sensitivity, specificity, positive predictive value (PPV), negative predictive value (NPV), and accuracy were calculated, and ROC analysis for the diagnosis of malignancy was performed.

**RESULTS.** A total of 697 women with 764 cystic lesions were included; 85.2% (651/764) of the lesions were nonneoplastic, 12.2% (93/764) were benign neoplasms, and 2.6% (20/764) were malignant neoplasms. Nearly all malignancies were classified into indeterminate and malignant categories. The prevalence of malignancy in the indeterminate category was 4.8% (7/145) (SRU) to 10.7% (7/65) (IOTA) and in the malignant category was 18.1% (13/72) (SRU) to 34.3% (12/35) (IOTA). Only one malignancy was misclassified as benign by the IOTA simple rules. The sensitivity of the IOTA simple rules for malignancy was 90.0%; specificity, 96.5%; PPV, 29.0%; NPV, 99.8%; and accuracy, 96.4%. The corresponding values for the SRU guidelines were 100%, 89.6%, 14.9%, 100%, and 89.8%. In ROC analysis, the IOTA simple rules were slightly more accurate than the SRU guidelines (AUC, 0.9805 versus 0.9713;  $p = 0.0003$ ).

**CONCLUSION.** Both imaging characterization methods were sensitive for identifying ovarian malignancies, but the PPV was low among women presenting to radiology departments, and the indeterminate classification harbored one-third of the total malignancies. Exploration of varied clinical settings and inclusion of secondary tests may help to refine these systems.

**U**ltrasound has a primary role in the assessment of adnexal abnormalities, having sensitivity of greater than 90% and specificity of 51–97% [1–3] for malignancy. Various sonographic criteria have been proposed for adnexal lesion characterization, including pattern recognition, morphologic indexing, and classification schemes based on the presence or absence of certain ultrasound findings [4, 5]. Formal image-based criteria and subjective evaluation based on the imager's experience can be used to characterize cystic adnexal lesions and guide recommendations.

**Keywords:** adnexal cyst, International Ovarian Tumor Analysis, IOTA, Society of Radiologists in Ultrasound, SRU, ultrasound

doi.org/10.2214/AJR.18.20630

Received September 5, 2018; accepted after revision July 26, 2019.

This article is available for credit.

AJR 2020; 214:694–700

0361–803X/20/2143–694

© American Roentgen Ray Society

<sup>1</sup>Department of Radiology, Vanderbilt University Medical Center, Medical Center North, Nashville, TN.

<sup>2</sup>Department of Radiology, University of Wisconsin School of Medicine and Public Health, Clinical Science Center, E3/372, 600 Highland Ave, Madison, WI 53792-3252. Address correspondence to E. A. Sadowski (esadowski@uwhealth.org).

<sup>3</sup>Department of Obstetrics and Gynecology, University of Wisconsin School of Medicine and Public Health, Madison, WI.

<sup>4</sup>Department of Radiology, Memorial Sloan Kettering Cancer Center, New York, NY.

<sup>5</sup>Montefiore Medical Center, Albert Einstein College of Medicine, Bronx, NY.

<sup>6</sup>Department of Biostatistics and Medical Informatics, University of Wisconsin—Madison, Madison, WI.

<sup>7</sup>Department of Radiology, University of Michigan Health System, Ann Arbor, MI.

<sup>8</sup>University of Michigan Health System, Ann Arbor, MI.

<sup>9</sup>Department of Obstetrics and Gynecology, University of Michigan Health System, Ann Arbor, MI.

## Ultrasound of Ovarian Cancer in Adnexal Cysts

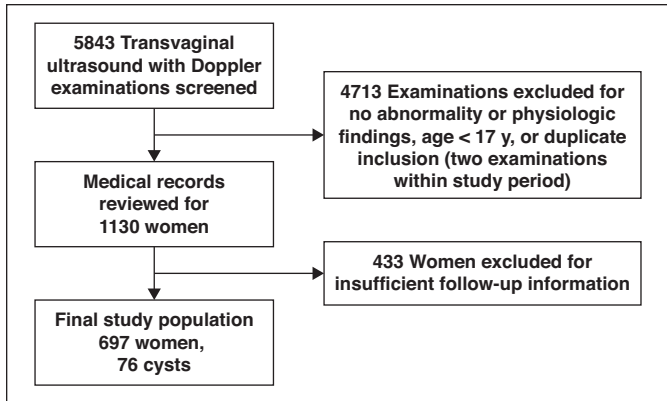


Fig. 1—Flowchart shows patient inclusion in final study population.

Simple ovarian cysts [6–8], classic hemorrhagic cysts, endometriomas, and dermoid cysts can usually be definitively characterized with ultrasound and have a very low risk of malignancy [9, 10]. In contrast, cystic lesions with internal solid components and nonshadowing solid masses with internal Doppler flow are suspicious for malignancy, particularly when ascites or peritoneal implants are present [11–13]. The ability to accurately risk stratify sonographically detected cystic lesions is important to avoid overtreatment of benign cystic lesions and to identify potentially malignant cystic tumors that require surgical evaluation.

Two major groups have published imaging criteria for characterization of adnexal lesions. The International Ovarian Tumor Analysis (IOTA) group [12–14] published the ultrasound-based simple rules, which are derived from regression analysis of sonographic features in a prospective study that included nearly 2000 women. The Society of Radiologists in Ultrasound (SRU) [11] published expert evidence-based consensus guidelines with criteria for characterization and management of asymptomatic adnexal cysts. The criteria set forth in the SRU guidelines help classify cysts as benign, indeterminate, and worrisome for malignancy to guide management and avoid excessive follow-up of physiologic and clinically inconsequential cysts.

The performance of the IOTA simple rules has been evaluated in subsequent studies by the primary investigators and others [12, 15–19]. The performance of the SRU guidelines in clinical practice has been evaluated in terms of decreasing the number of follow-up examinations [20] and accurately triaging cysts into risk groups [21]. However, the comparative performance of these two methods has not been formally evaluated, to our knowledge. The goal of this study was

to compare the performance of the IOTA simple rules with that of the SRU consensus guidelines for detecting ovarian malignancy in women with adnexal cystic lesions presenting to radiology departments at academic medical centers.

### Materials and Methods

#### Subjects and Inclusion

This HIPAA-compliant multicenter retrospective cohort study received institutional review board approval from four participating institutions with the requirement for informed consent waived. Investigators reviewed images from transabdominal and transvaginal ultrasound examinations (Logiq 9 or E9, GE Healthcare, or iU22, Philips Healthcare, machines) performed between January 2008 and June 2012 for adnexal cystic lesions. Only patients who underwent both transabdominal and transvaginal ultrasound were included in the final analysis. Data on adnexal cystic lesions were collected between January 2015 and July 2017. A subset of the data, on 500 of the 697 patients, was previously published [21]. The prior study assessed the performance of the SRU guidelines in appropriately risk stratifying cystic lesions; in the current study, we compared the IOTA simple rules and SRU guidelines for detecting ovarian malignancy in women with adnexal cystic lesions.

#### Initial Lesion Inclusion Criteria

Cystic adnexal lesions in women 17 years old or older were included, except for simple cysts smaller than 1 cm, classic corpus luteal cysts, and completely solid lesions. Classic corpus luteal cysts were defined according to the SRU guidelines. Electronic medical records were reviewed for age, menopausal status, follow-up type, pathologic diagnosis, and clinical physical examinations. Only lesions with adequate follow-up were included in the image review and final analysis. Adequate follow-up was defined as pathologic diagnosis, res-

olution or decrease in size at follow-up imaging, or documented normal pelvic examination findings more than 2 years after the initial pelvic ultrasound. Patient inclusion is depicted in Figure 1.

#### Image Analysis

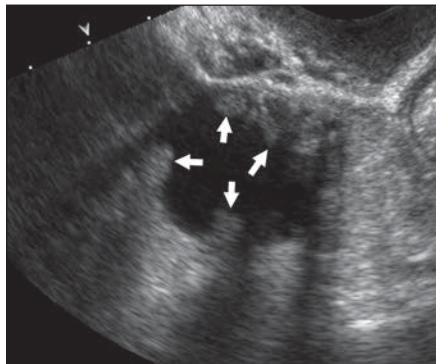
At each institution, image analysis was performed at a PACS workstation (Syngo Dynamics, Siemens Healthineers; McKesson PACS, McKesson Radiology; or GE Centricity, GE Healthcare). The images were reviewed by one of six primary readers, who were fellowship-trained abdominal radiologists with 1–16 years of postresidency training. The following lesion characteristics were recorded: greatest diameter; side; presence of solid components (i.e., number and type of septations, number and greatest diameter of nodules and papillary excrescences); acoustic shadowing; absent, weak, or strong Doppler flow in solid components; and presence of ascites or peritoneal implants. The primary reader then classified each cystic lesion into benign, indeterminate, or malignant categories according to criteria based on the IOTA simple rules and SRU guidelines as shown in Table 1. Examples of lesions classified as concordant and discordant according to the SRU criteria and IOTA simple rules are shown in Figures 2 and 3.

The IOTA three simple rules scheme assesses five benign features and five malignant features. Benign features include any size of unilocular cyst, presence of solid components smaller than 7 mm in diameter, acoustic shadowing, smooth multilocular tumor smaller than 100 mm, and no Doppler blood flow. Malignant features include irregular solid tumor, ascites, at least four papillary structures, irregular multilocular solid tumor measuring 100 mm or larger, and very strong Doppler blood flow in the solid component [13]. The three simple rules shown in Table 1 were followed for all lesions. One of the investigators attended the IOTA certification course, received certification in this technique, supervised the data collection, and reviewed scoring in all cases.

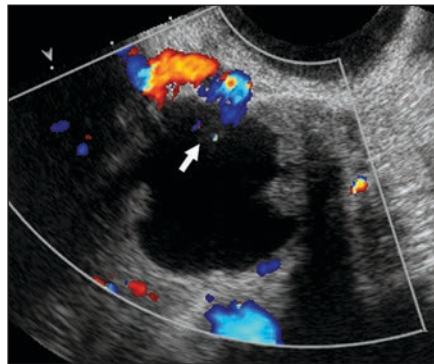
The SRU guidelines describe criteria for characterizing adnexal lesions but do not specifically define benign, indeterminate, or malignant categories. Therefore, for this analysis we grouped the published SRU guideline criteria into three categories as follows. We assumed that if the SRU guidelines recommended surgical consultation, the categorization was malignant. If the guidelines recommended imaging follow-up, the categorization was benign or indeterminate based on criteria outlined in the published guidelines and shown in Table 1 [11]. We followed the SRU imaging criteria for the diagnosis of simple cysts, dermoid cysts, endometriomas, and hemorrhagic

**TABLE 1: Criteria for Assigning Benign, Indeterminate, or Malignant Category Based on International Ovarian Tumor Analysis (IOTA) Simple Rules and Society of Radiologists in Ultrasound (SRU) Guidelines**

Method	Malignant Category	Benign Category	Indeterminate Category
IOTA simple rules	Rule 1—if one or more malignant features is present in the absence of any benign features, the lesion is malignant	Rule 2—if one or more benign features is present in the absence of any malignant features, the lesion is benign	Rule 3—if both benign and malignant features are present, the lesion is indeterminate
SRU guidelines	Thick septations ( $\geq 3$ mm)	Typical simple cyst $< 7$ cm in diameter, any age	Cyst with avascular soft tissue nodule, any age
	Solid elements or nodules with blood flow	Typical hemorrhagic cysts, any size, premenopausal woman	Cyst with multiple ( $\geq 3$ ) thin ( $< 3$ mm) septations
	Hemorrhagic cysts, postmenopausal woman	Typical dermoid or endometrioma, any age	Atypical hemorrhagic cyst or endometrioma or dermoid, premenopausal woman
	Atypical dermoid or endometrioma, postmenopausal woman		Incompletely evaluated simple cyst $> 7$ cm, any age



**A**



**B**

**Fig. 2**—35-year-old woman with borderline serous tumor. Example of concordant classification according to Society of Radiologists in Ultrasound (SRU) criteria and International Ovarian Tumor Analysis (IOTA) simple rules. Cyst was classified as malignant at imaging with both SRU criteria and IOTA simple rules because there are at least four papillary projections and blood flow within papillary projection at color Doppler imaging.

**A**, Gray-scale ultrasound image shows 3.3-cm cystic lesion in right adnexa with multiple ( $\geq 4$ ) papillary projections (*arrows*) along wall of cyst.  
**B**, Color Doppler image depicts blood flow within papillary projection (*arrow*).

cysts. In addition to the published criteria, we assumed the following: cystic lesions with multiple ( $\geq 3$ ) thin ( $< 3$  mm) septations were classified as indeterminate. We classified all hemorrhagic cysts larger than 1 cm in postmenopausal women in this study as potentially malignant, because we did not have data available to separate the postmenopausal group in our study into early and late cohorts. Menopausal status was defined as no menstrual periods for 12 months.

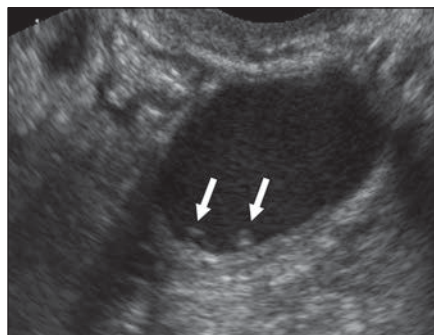
After initial IOTA and SRU classification, a second reader blinded to the primary reader's classification applied Microsoft Excel 2016 formulas based on recorded cyst features to cross-check the assignment by the primary reader. Any discordant cystic lesions were reviewed for data input integrity. After rereview of the images and verification of the presence or absence of an imaging characteristic, the assigned classification was corrected.

**Statistical Analysis**

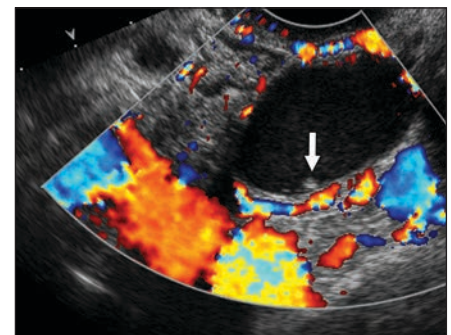
Simple descriptive statistics were used to assess the demographic and cystic lesion characteristics. Continuous variables were expressed as mean  $\pm$  SD. Categorical variables were expressed as frequency and percentage. Sensitivity, specificity, positive predictive value (PPV), negative predictive value (NPV), and accuracy for the diagno-

sis of malignancy were calculated. Cystic lesions classified as indeterminate on the basis of imaging findings were excluded from this analysis. When a patient had two cystic lesions, the more worrisome cystic lesion was included in the calculations of sensitivity, specificity, PPV, NPV, and accuracy. ROC analysis was performed to compare the di-

agnostic accuracy of the two methods (IOTA simple rules versus SRU guidelines) for predicting the final benign versus malignant outcome. The null hypothesis that the AUC values for the two correlated ROC curves are the same was tested by use of the theory of generalized *U* statistics. A value of *p*  $< 0.05$  was considered statistically significant.



**A**



**B**

**Fig. 3**—43-year-old woman with serous cystadenoma with focal area of atypia. Example of discordant classification by classification according to Society of Radiologists in Ultrasound (SRU) criteria and International Ovarian Tumor Analysis (IOTA) simple rules. Cyst was classified as indeterminate at imaging according to SRU criteria because of papillary projections along posterior wall that did not have any Doppler flow within them. Lesion was classified as benign according to IOTA simple rules because it did not have at least four papillary projections.

**A**, Gray-scale ultrasound image shows 3-cm cystic lesion in left adnexa with two small ( $< 3$  mm) papillary projections (*arrows*) along posterior wall of cyst.  
**B**, Color Doppler image depicts no blood flow within papillary projections (*arrow*).



## Ultrasound of Ovarian Cancer in Adnexal Cysts

**TABLE 2: Patient Demographics and Characteristics of Adnexal Cystic Lesions**

Characteristic	Value
No. of women	697
Age (y)	
Mean ± SD	41.9 ± 13.6
Range	17–91
Menopausal status	
Premenopausal	532 (76.3)
Postmenopausal	165 (23.7)
Indication on ultrasound requisition	
Pain, bloating, fullness	326 (46.8)
Abnormal vaginal bleeding	107 (15.4)
Palpable mass at physical examination	15 (2.1)
Incidental adnexal mass at CT or MRI	125 (17.9)
Nonadnexal indications (e.g., fibroids or intrauterine device)	124 (17.8)
Total no. of cysts	764
Greatest diameter (cm)	
Mean ± SD	4.2 ± 2.7
Range	1.0–20.7
No. of benign nonneoplastic cysts	651 (85.2)
No. of benign neoplasms	93 (12.2)
No. of malignant cystic tumors	20 (2.6)

Note—Values in parentheses are percentages.

Stata software (version 15, StataCorp) was used for all analyses.

### Results

#### Patients

The study included 697 women (age range, 17–91 years; mean, 41.9 ± 13.6 years; 532

[76.3%] premenopausal; 165 [23.7%] postmenopausal) (Table 2). After initial IOTA and SRU classification, there were 27 lesions which were discordant after application of the Microsoft Excel formulas based on recorded cyst features. These lesions were re-reviewed to verify the presence or absence of the recorded cyst features, and the assigned classification was corrected.

#### Cystic Lesion Outcomes

A total of 764 cystic lesions were included: 489 (64.0%) based on follow-up imaging, 231 (30.2%) based on surgical pathologic result, and 44 (5.8%) based on normal follow-up pelvic examination findings after more than 2 years. The cystic lesions ranged in size from 1 to 20.7 cm with a mean greatest diameter of 4.2 ± 2.7 cm.

Of the 764 cystic lesions, 651 (85.2%) were nonneoplastic, 93 (12.2%) were benign neoplasms, and 20 (2.6%) were malignant cystic tumors (Table 2). Approximately one-third (7/20) of the pathologically diagnosed malignancies were classified as indeterminate, and two-thirds were classified as malignant (12–13/20) on the basis of imaging categories. The prevalence of malignancy in the indeterminate category was 4.8% (7/145) for SRU and 10.7% (7/65) for IOTA. The prevalence of malignancy in the malignant category was 18.1% (13/72) for SRU and 34.3% (12/35) for IOTA (Table 3). Only one malignancy was misclassified, as benign, with the IOTA simple rules (Fig. 4).

The most common malignancies were high-grade tumors (9/20). The other malignancies were borderline tumors (4/20), low-grade tumors (3/20), clear cell carcinomas (2/20), moderate-grade tumor (1/20), and metastatic disease (1/20). The mean age of

women with malignant cystic tumors was 59.0 ± 15.0 years (range, 31–87 years). The size range of the malignant cystic tumors was 2.4–20.0 cm with no to five septations, no to five nodular components with nodular components measuring up to 5.6 cm, and variable Doppler flow ranging from no blood flow to strong blood flow at subjective analysis.

Most of the benign neoplasms were cystadenomas or cystadenofibromas (76/93). The other benign neoplasms were mature dermoid cysts (16/93) and a cystic fibrothecoma (1/93). The mean age of women with benign neoplasms was 49 ± 15 years (range, 17–85 years). The range of greatest diameter of the cystic lesions was 2.3–20.2 cm, and the mean was 6.3 ± 4.1 cm. Nearly one-half of the benign cystic lesions, 44.1% (41/93), were simple in appearance; the others contained septations or solid-appearing nodules with or without blood flow.

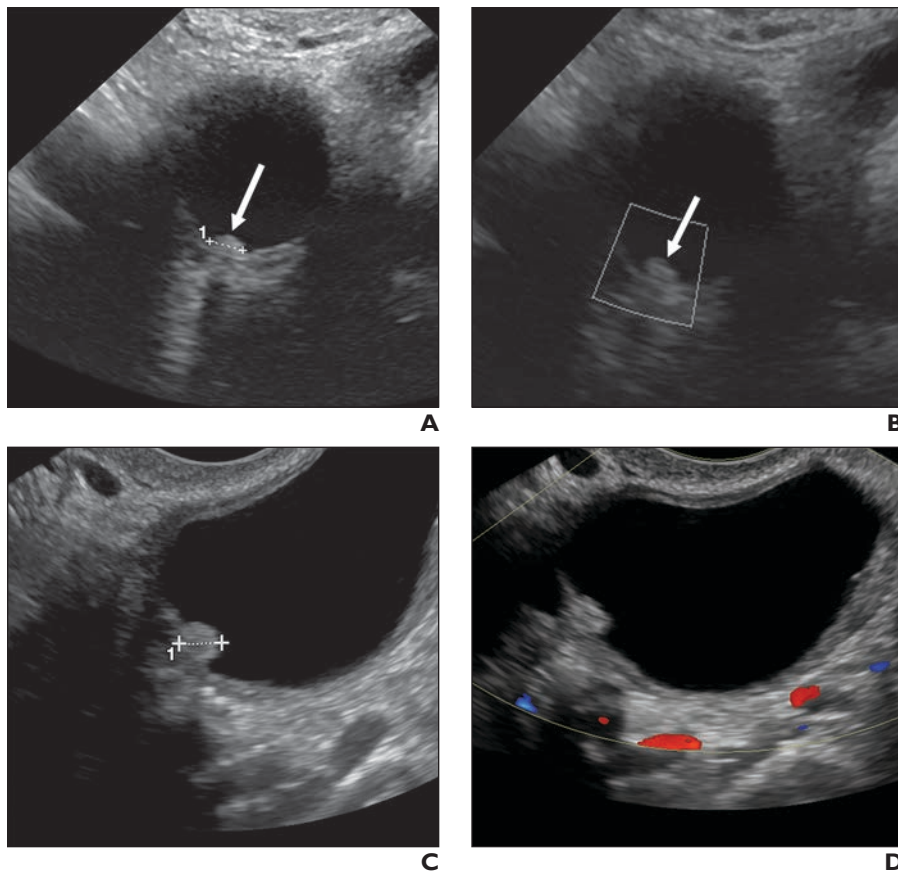
#### International Ovarian Tumor Analysis Simple Rules

With respect to the 764 cystic lesions, readers applying the IOTA simple rules classified 664 (86.9%) as benign, 65 (8.5%) as indeterminate, and 35 (4.6%) as malignant. The frequencies of nonneoplastic, benign neoplastic, and malignant cystic tumors found at pathologic analysis in each image-based classification category are shown in Table 3. Of the malignant cystic tumors, 12 of 20 were classified as malignant on the basis of imaging findings, 7 of 20 as indeterminate, and 1 of 20 as benign. In the single case of a malignant cystic tumor classified as benign at imaging according to the IOTA simple rules (Fig. 4), the cystic lesion was eventually removed because was found to have enlarged at follow-up imaging. The sensitivity of the

**TABLE 3: Frequency of Types of Cystic Lesions According to Ultrasound Classification Methods Based on the International Ovarian Tumor Analysis (IOTA) Simple Rules and the Society of Radiologists in Ultrasound (SRU) Guidelines**

Ultrasound Diagnosis Category	No. of Cystic Lesions	Frequency		
		Nonneoplastic Cysts	Benign Neoplasms	Malignant Cystic Tumors
IOTA simple rules				
Malignant	35	11 (31.4)	12 (34.3)	12 (34.3)
Benign	664	592 (89.2)	71 (10.7)	1 (0.1)
Indeterminate	65	48 (73.9)	10 (15.4)	7 (10.7)
SRU guidelines				
Malignant	72	45 (62.5)	14 (19.4)	13 (18.1)
Benign	547	517 (94.5)	30 (5.5)	0 (0)
Indeterminate	145	89 (61.4)	49 (33.8)	7 (4.8)

Note—Values in parentheses are percentages.



**Fig. 4**—60-year-old woman with stage I endometrioid cancer. Cystic lesion was discordant according to Society of Radiologists in Ultrasound (SRU) criteria and International Ovarian Tumor Analysis (IOTA) simple rules. It was indeterminate according to SRU criteria owing to presence of avascular nodule and benign according to IOTA simple rules because solid component was smaller than 7 mm with no blood flow. **A**, Gray-scale baseline ultrasound image depicts 2.5-cm cystic lesion in right ovary with 4-mm soft-tissue nodule (arrow and cursors) along wall. **B**, Color Doppler ultrasound image shows no blood flow within soft-tissue nodule (arrow). **C**, Gray-scale ultrasound image obtained approximately 18 months after **A** and **B** shows 3.3-cm cystic lesion in right ovary with 5-mm soft-tissue nodule (cursors) along wall. **D**, Color Doppler image shows no blood flow within soft-tissue nodule.

IOTA simple rules for the diagnosis of a malignant tumor when a cystic lesion was classified as malignant on the basis of ultrasound findings was 90%; specificity, 96.5%; PPV, 29%; NPV, 99.8%; and accuracy, 96.4%.

#### Society of Radiologists in Ultrasound Guidelines

With respect to the 764 cystic lesions, readers applying the SRU guidelines classified 547 (71.6%) as benign, 145 (19.0%) as indeterminate, and 72 (9.4%) as malignant. The frequencies of nonneoplastic, benign neoplastic, and malignant cystic tumors found at pathologic analysis in each image-based classification category are presented in Table 3. Of the malignant cystic tumors, all were classified as either malignant (13/20) or indeterminate (7/20). The sensitivity of the SRU guidelines for the diagnosis of a malignant tumor when

a cystic lesion was classified as malignant was 100%; specificity, 89.6%; PPV, 14.9%; NPV, 100%; and accuracy, 89.8%.

#### Comparing the International Ovarian Tumor Analysis Simple Rules and Society of Radiologists in Ultrasound Guidelines

In ROC analysis, the AUC for the diagnosis of malignancy was 0.98 for the IOTA simple rules and 0.97 for the SRU guidelines ( $p = 0.0003$ ) (Fig. 5). The IOTA simple rules method was slightly more accurate than the SRU guidelines. Both methods were highly sensitive for malignancy, but substantially fewer benign lesions were categorized as indeterminate and malignant with the IOTA simple rules: 145 of 764 benign lesions (19.0%) were classified as indeterminate and 72 (9.4%) as malignant according to SRU,

and 65 of 764 (8.5%) were classified as indeterminate and 35 (4.6%) as malignant according to IOTA.

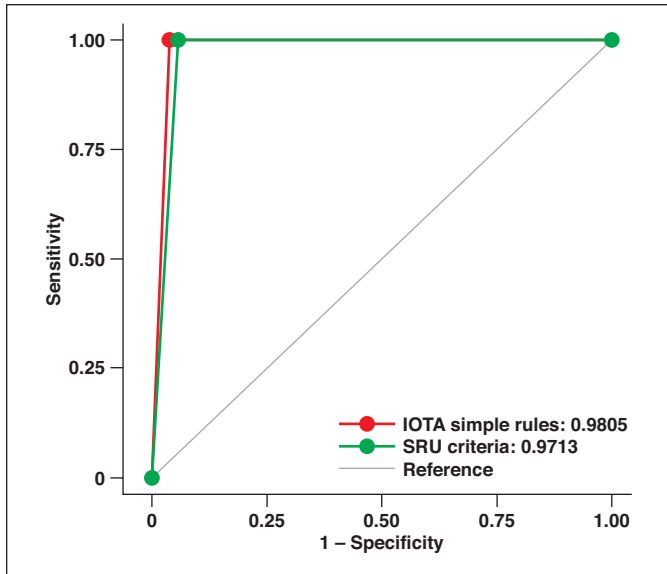
#### Discussion

The goal of an image-based classification system is to characterize adnexal lesions as benign or possibly malignant. In this study, we used two methods—the IOTA simple rules and the criteria described in the SRU consensus guidelines—to classify adnexal cystic lesions in a general population of women presenting to academic radiology departments. All 20 malignancies were classified according to the SRU guidelines into indeterminate or malignant categories. One early-stage endometrioid carcinoma was classified as benign according to the IOTA simple rules. The SRU guidelines were more sensitive (100%), and the IOTA simple rules were more specific (96.5%) for malignancy. Our results are similar to previously reported sensitivities and specificities for image-based adnexal lesion classification systems [4, 5, 22–24]. Both the IOTA simple rules and the SRU guidelines had high NPVs (99.8–100%) for excluding malignancy, and low PPVs (14.9–29%) for malignancy.

From ROC analysis, the performance of the IOTA simple rules was slightly more accurate than that of the SRU guidelines for the diagnosis of malignancy ( $p < 0.003$ ) because fewer benign lesions were misclassified into the indeterminate and malignant categories with the IOTA simple rules. The clinical relevance of this small difference in clinical practice is uncertain. Using these image-based criteria in clinical practice depends on the goals of the practice. If ultrasound is used predominantly as a screening tool to exclude cancer, then the higher sensitivity and NPV of the SRU guidelines would tip the scales toward this approach. On the other hand, if the primary goal of ultrasound is lesion characterization and treatment planning, the higher specificity and PPV of the IOTA simple rules would favor their use.

In our study, both indeterminate and malignant categories harbored malignant lesions; approximately one-third of pathologically proven malignancies were categorized into the indeterminate group by use of SRU guidelines and IOTA simple rules. The prevalence of malignancy in the indeterminate category was 4.8% (7/145) for SRU to 10.7% (7/65) for IOTA and in the malignant category was 18.1% (13/72) for SRU to 34.3% (12/35) for IOTA. Previous investigators

## Ultrasound of Ovarian Cancer in Adnexal Cysts



**Fig. 5**—Graph shows comparison of performance of International Ovarian Tumor Analysis (IOTA) simple rules (AUC, 0.9805) and Society of Radiologists in Ultrasound (SRU) guidelines (AUC, 0.9713) for diagnosis of malignant tumor ( $p = 0.0003$ ).

have reported the prevalence of malignancy within ultrasound indeterminate lesions as ranging between 5% and 40%, depending on the inclusion criteria and reader experience [12, 25, 26]. The SRU guidelines call for referring patients with lesions categorized as indeterminate for either imaging follow-up or surgical consultation [11]. Referring for imaging surveillance risks losing the window for catching early-stage cancer, whereas referring for surgery risks overtreatment. Secondary examinations such as MRI can help avoid unnecessary surgical referrals [21, 27]. A 2017 study [21] showed that use of MRI can reduce the number of surgical evaluations for benign cysts by 89%. This is not surprising given that MRI has a high NPV (100%) when there is a lack of solid tissue enhancement [28].

In our study, a lesion categorized as benign carried little to no risk of malignancy (NPV, 99.8–100%). However, 5–10% of the lesions characterized as benign according to imaging criteria were benign neoplasms, such as dermoid cysts and cystadenomas, and one early-stage ovarian carcinoma was classified as benign with the IOTA simple rules. Our study was not designed to determine which lesions classified as benign on the basis of image-based criteria require follow-up. However, the findings of our study underscore the need for additional research to determine the role of follow-up of benign-appearing lesions, some of which may ultimately be found to be benign neoplasms or very early ovarian cancer [11]. Follow-up imaging was helpful in the case of the patient in Figure 4, who was un-

dergoing follow-up because the original clinical reader recommended additional follow-up because of a single small (4 mm) avascular papillary projection. This lesion did exhibit ultrasound evidence of continued growth, eventually prompting removal of this stage I endometrioid cancer.

With both methods, a malignant image-based categorization conveyed some risk of malignancy (PPV, 14.9–29.0%). However, the PPV in our study cohort is lower than that of the cohort studied by the IOTA group [12]; a PPV of 87% can be extrapolated from their results. This disparity likely arises from differences in the populations analyzed, technical expertise of the person performing the ultrasound examination (sonographer versus physician), and cancer incidence. In our study, we evaluated lesions in a population of women presenting to academic radiology departments for a variety of indications who underwent scanning performed by sonographic technologists, and only one-third of the women underwent surgery. The 2010 IOTA study [12] evaluated a population referred to a gynecologist for a suspected adnexal mass, the ultrasound was performed by trained gynecologists or radiologists with more than 5 years' experience, and all women underwent surgery. The prevalence of malignancy in our population was 2.6% versus the 27.9% in the IOTA study; the higher prevalence of cancer increases the PPV.

A 2018 study [29] also showed lower PPV with the IOTA simple rules in an outpatient setting. The authors of that study noted that in the outpatient setting, the IOTA simple

rules retained high sensitivity, but the lower specificity indicated the need for a secondary test to help minimize false-positive findings. These differences in performance of the IOTA simple rules between studies underscore the potential variable performance of image-based classification systems related to patient population, practice setting, and prevalence of cancer [22, 29].

The major limitations of our study were that our population was primarily premenopausal with a high number of benign lesions and low prevalence of malignancy and that our retrospective approach did not allow control over ultrasound image quality and technical parameters. These image-based classification methods may perform differently in different populations and practice conditions. In addition, inherent in the retrospective approach is potential sampling bias in this population because a portion of the patients were lost to follow-up (38%). It is not known whether the lesions in these patients were ultimately found to be benign or malignant. Finally, a three-category system (malignant, benign, indeterminate) for the SRU guidelines had to be applied post hoc for the comparative analysis between the two methods. This required making several inferences to create the numeric categorization, which might not completely reflect the thoughts of the SRU expert panel. There also was a limitation in regard to differences between the SRU guidelines and IOTA simple rules in years of training and level of familiarity, which may have affected the results.

### Conclusion

Image-based classification systems are sensitive for the identification of ovarian malignancy. However, the PPV is low in a general population of predominately premenopausal women presenting to radiology departments, and the indeterminate classification harbored one-third of the total malignancies. Exploration of varied clinical settings and inclusion of secondary tests may help to refine these systems and achieve the balanced goals of avoiding inappropriate surgery for benign cystic lesions and expediting the care of women with potentially malignant cystic tumors.

### Acknowledgment

We thank members of the Society of Abdominal Radiology Uterine and Ovarian Cancer Disease-Focused Panel for performing research for this study.



## References

1. Brown DL, Doubilet PM, Miller FH, et al. Benign and malignant ovarian masses: selection of the most discriminating gray-scale and Doppler sonographic features. *Radiology* 1998; 208:103–110
2. Valentin L. Prospective cross-validation of Doppler ultrasound examination and gray-scale ultrasound imaging for discrimination of benign and malignant pelvic masses. *Ultrasound Obstet Gynecol* 1999; 14:273–283
3. Medeiros LR, Rosa DD, da Rosa MI, Bozzetti MC. Accuracy of ultrasonography with color Doppler in ovarian tumor: a systematic quantitative review. *Int J Gynecol Cancer* 2009; 19:230–236
4. Alcázar JL, Mercé LT, Laparte C, Jurado M, López-García G. A new scoring system to differentiate benign from malignant adnexal masses. *Am J Obstet Gynecol* 2003; 188:685–692
5. Amor F, Alcázar JL, Vaccaro H, León M, Iturra A. GI-RADS reporting system for ultrasound evaluation of adnexal masses in clinical practice: a prospective multicenter study. *Ultrasound Obstet Gynecol* 2011; 38:450–455
6. Valentin L, Ameye L, Franchi D, et al. Risk of malignancy in unilocular cysts: a study of 1148 adnexal masses classified as unilocular cysts at transvaginal ultrasound and review of the literature. *Ultrasound Obstet Gynecol* 2013; 41:80–89
7. Greenlee RT, Kessel B, Williams CR, et al. Prevalence, incidence, and natural history of simple ovarian cysts among women >55 years old in a large cancer screening trial. *Am J Obstet Gynecol* 2010; 202:373
8. Modesitt SC, Pavlik EJ, Ueland FR, DePriest PD, Kryscio RJ, van Nagell JR Jr. Risk of malignancy in unilocular ovarian cystic tumors less than 10 centimeters in diameter. *Obstet Gynecol* 2003; 102:594–599
9. Kido A, Togashi K, Konishi I, et al. Dermoid cysts of the ovary with malignant transformation: MR appearance. *AJR* 1999; 172:445–449
10. Munksgaard PS, Blaakaer J. The association between endometriosis and gynecological cancers and breast cancer: a review of epidemiological data. *Gynecol Oncol* 2011; 123:157–163
11. Levine D, Brown DL, Andreotti RF, et al. Management of asymptomatic ovarian and other adnexal cysts imaged at US: Society of Radiologists in Ultrasound Consensus Conference Statement. *Radiology* 2010; 256:943–954
12. Timmerman D, Ameye L, Fischerova D, et al. Simple ultrasound rules to distinguish between benign and malignant adnexal masses before surgery: prospective validation by IOTA group. *BMJ* 2010; 341:c6839
13. Timmerman D, Testa AC, Bourne T, et al. Simple ultrasound-based rules for the diagnosis of ovarian cancer. *Ultrasound Obstet Gynecol* 2008; 31:681–690
14. Timmerman D, Valentin L, Bourne TH, Collins WP, Verrelst H, Vergote I. International Ovarian Tumor Analysis (IOTA) Group. Terms, definitions and measurements to describe the sonographic features of adnexal tumors: a consensus opinion from the International Ovarian Tumor Analysis (IOTA) Group. *Ultrasound Obstet Gynecol* 2000; 16:500–505
15. Nunes N, Ambler G, Foo X, Naftalin J, Widschwendter M, Jurkovic D. Use of IOTA simple rules for diagnosis of ovarian cancer: meta-analysis. *Ultrasound Obstet Gynecol* 2014; 44:503–514
16. Fathallah K, Huchon C, Bats AS, et al. External validation of simple ultrasound rules of Timmerman on 122 ovarian tumors [in French]. *Gynecol Obstet Fertil* 2011; 39:477–481
17. Alcázar JL, Pascual MA, Graupera B, et al. External validation of IOTA simple descriptors and simple rules for classifying adnexal masses. *Ultrasound Obstet Gynecol* 2016; 48:397–402
18. Sayasneh A, Wynants L, Preisler J, et al. Multicentre external validation of IOTA prediction models and RMI by operators with varied training. *Br J Cancer* 2013; 108:2448–2454
19. Hartman CA, Juliato CRT, Sarian LO, et al. Ultrasound criteria and CA 125 as predictive variables of ovarian cancer in women with adnexal tumors. *Ultrasound Obstet Gynecol* 2012; 40:360–366
20. Ghosh E, Levine D. Recommendations for adnexal cysts: have the Society of Radiologists in Ultrasound consensus conference guidelines affected utilization of ultrasound? *Ultrasound Q* 2013; 29:21–24
21. Maturen KE, Blaty AD, Wasnik AP, et al. Risk stratification of adnexal cysts and cystic masses: clinical performance of Society of Radiologists in Ultrasound guidelines. *Radiology* 2017; 285:650–659
22. Timmerman D, Van Calster B, Testa A, et al. Predicting the risk of malignancy in adnexal masses based on the Simple Rules from the International Ovarian Tumor Analysis group. *Am J Obstet Gynecol* 2016; 214:424–437
23. DePriest PD, Shenson D, Fried A, et al. A morphology index based on sonographic findings in ovarian cancer. *Gynecol Oncol* 1993; 51:7–11
24. Ferrazzi E, Zanetta G, Dordoni D, Berlanda N, Mezzopane R, Lissoni AA. Transvaginal ultrasonographic characterization of ovarian masses: comparison of five scoring systems in a multicenter study. *Ultrasound Obstet Gynecol* 1997; 10:192–197
25. Adusumilli S, Hussain HK, Caoili EM, et al. MRI of sonographically indeterminate adnexal masses. *AJR* 2006; 187:732–740
26. Sadowski EA, Paroder V, Patel-Lippmann K, et al. Indeterminate adnexal cysts at US: prevalence and characteristics of ovarian cancer. *Radiology* 2018; 287:1041–1049
27. Kinkel K, Lu Y, Mehdizade A, Pelte MF, Hricak H. Indeterminate ovarian mass at US: incremental value of second imaging test for characterization—meta-analysis and Bayesian analysis. *Radiology* 2005; 236:85–94
28. Thomassin-Naggara I, Aubert E, Rockall A, et al. Adnexal masses: development and preliminary validation of an MR imaging scoring system. *Radiology* 2013; 267:432–443
29. Nunes N, Ambler G, Foo X, Widschwendter M, Jurkovic D. A prospective evaluation of the IOTA logistic regression models (LR1 and LR2) in comparison to subjective pattern recognition for the diagnosis of ovarian cancer in the outpatient setting. *Ultrasound Obstet Gynecol* 2018; 51:829–835

## FOR YOUR INFORMATION

ARRS is accredited by the Accreditation Council for Continuing Medical Education (ACCME) to provide continuing medical education activities for physicians.

The ARRS designates this journal-based CME activity for a maximum of 1.00 *AMA PRA Category 1 Credits*™ and 1.00 *American Board of Radiology*©, MOC Part II, Self-Assessment CME (SA-CME). Physicians should claim only the credit commensurate with the extent of their participation in the activity.

To access the article for credit, follow the prompts associated with the online version of this article.