Computed Tomography of the Spleen and Liver in Sickle Cell Disease

Donna Magid[1]
Elliot K. Fishman
Stanley S. Siegelman

The spleen was assessed in 10 patients with sickle cell disease studied with computed tomography (CT) for abdominal pain and/or unexplained fever. Patients with homozygous sickle cell anemia were found to have small, densely calcified spleens with occasional low-density infarcts. Five of six had hepatomegaly, and there was one case each of hepatic abscess, infarcts, and hemochromatosis. All patients with heterozygous sickle cell disease were found to have splenomegaly, with a variety of findings including acute hemorrhage, acute and chronic infarcts, rupture, and possible sequestration. It was concluded that CT is useful for evaluating the status of the spleen and liver in symptomatic patients with sickle cell disease.

Sickle cell disease is perhaps the most common of human hereditary disorders. In this country, sickle cell anemia, the homozygous form of the disease, affects one of 500 black fetuses at conception and one of 600 black infants at birth, while sickle cell trait is found in 8%–10% of the black population [1–3]. The term *sickle cell disease* also encompasses rarer forms of double-heterozygous disease such as sickle-C, sickle-thalassemia, sickle-D Punjab, and sickle-O Arab. These patients frequently require medical care for painful vasoocclusive crises; it is not unusual in our series for adult homozygous patients to have had over 100 documented emergency room visits. Computed tomography (CT) demonstrates splenic abnormalities in virtually all of these patients; especially in the heterozygous patient, it may be able to clarify complex and confusing clinical problems.

Subjects and Methods

Fourteen CT studies were performed in 10 patients in whom the diagnosis of sickle cell anemia or a sickle cell variant had been established by clinical findings, family history, serum electrophoresis, and sickle cell preparation. Six patients were homozygous for sickle cell anemia (17-, 19-, and 31-year-old men; 27-, 29-, and 54-year-old women). The rest were heterozygous, including one with sickle cell trait (36-year-old man), two with sickle-C disease (15-year-old boy and 49-year-old woman), and one with sickle-thalassemia (43-year-old woman). All patients were studied because of abdominal pain. Other clinical factors included suspected surgical abdomen (three cases), fever and leukocytosis (two), suspected vasoocclusive crisis (three), chronic left upper quadrant pain (one), and suspicion of pancreatic pseudocyst (one).

Examinations were performed on a Siemens Somatom DR-3 scanner using 125 kVp, 3.2 sec, 230 mA, and 4 or 8 mm slice thickness, or on a Pfizer-AS&E 0500 scanner with scanning techniques of 120 kVp, 10 sec, 20 mA, and 10 mm collimation. Patients received three oral doses of 240 ml each of a flavored 3% solution of Hypaque at 20 min intervals beginning 60 min before the examination. Scans were obtained at 1 cm intervals from the level of the diaphragm through the liver and spleen and continued caudally at 2 cm intervals to the symphysis pubis, with additional scans as needed.

Results

All 10 patients had splenic abnormalities detected by CT. Four of the six

Received February 5, 1984; accepted after revision April 19, 1984.

[1]All authors: Russell H. Morgan Department of Radiology and Radiological Science, Johns Hopkins Medical Institutions, 600 N. Wolfe St., Baltimore, MD 21205. Address reprint requests to D. Magid.

AJR 143:245–249, August 1984
0361–803X/84/1432–0245
© American Roentgen Ray Society

Downloaded from www.ajronline.org by 65.21.193.86 on 02/24/22 from IP address 65.21.193.86. Copyright ARRS. For personal use only; all rights reserved

Downloaded from www.ajronline.org by 65.21.193.86 on 02/24/22 from IP address 65.21.193.86. Copyright ARRS. For personal use only; all rights reserved

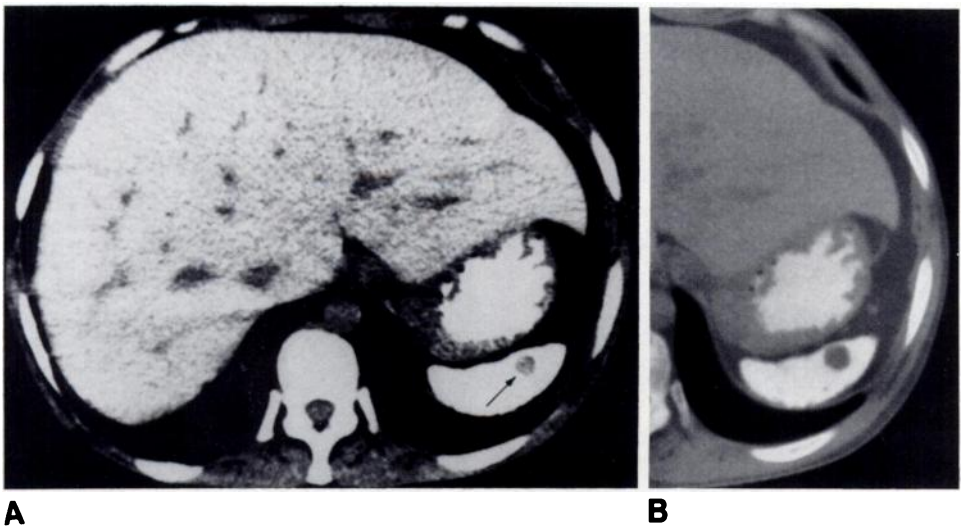

Fig. 1.—31-year-old man with homozygous disease who presented in crisis with abdominal pain. **A**, Hepatomegaly with increased attenuation of liver. Liver attenuation was about 110 H, consistent with hemochromatosis, which was proven by biopsy. Spleen is densely calcified and shrunken. Small zone of residual noncalcified splenic tissue (*arrow*) (window center, 39 H; window width, 150 H). **B**, Detail in calcified spleen is noted (window center, 90 H; window width, 1256 H).

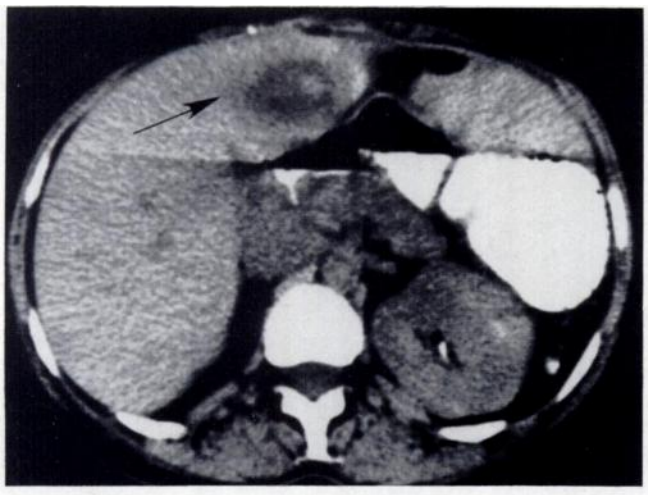

Fig. 2.—27-year-old woman with homozygous disease who presented with right upper quadrant pain, jaundice, and fever. Low-density lesion in left lobe of liver (*arrow*) was puncture-proven hepatic abscess. Left kidney is large with areas of low density, compatible with homozygous sickle cell disease with renal infarcts.

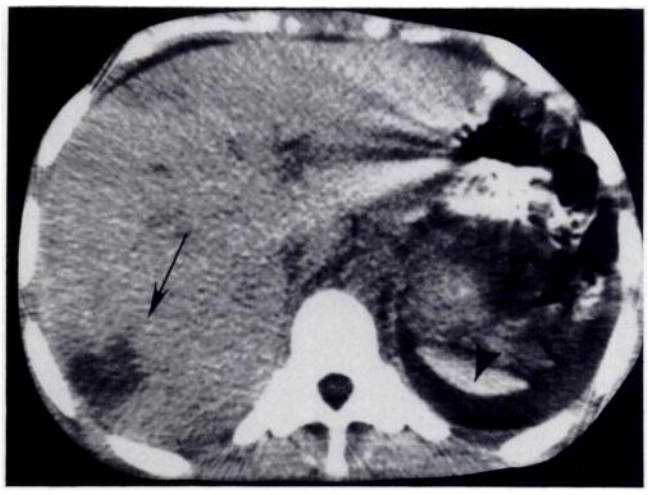

Fig. 3.—19-year-old man with homozygous disease and systemic lupus erythematosus who presented with abdominal pain and cavitary lung lesion. Peripheral low-density zones in liver (*arrow*) were autopsy-proven infarcts. Shrunken calcified spleen (*arrowhead*).

homozygous sickle cell anemia patients had small, densely calcified spleens correlating with the well known sequence of early infarction and fibrosis that produces functional autosplenectomy in this disease (figs. 1–3). Presumed splenic nonfunction was correlated with splenic nonvisualization on ^{99m}Tc sulfur-colloid liver-spleen scans and by peripheral blood smears compatible with functional asplenia. Two homozygous patients were found to have spleens nearly normal in size but densely calcified (fig. 4). Hepatic abnormalities were also noted; hepatomegaly was noted in five of six homozygous patients. Liver enlargement was associated with biopsy-proven hemochromatosis in one (fig. 1), puncture-proven liver abscesses in one (fig. 2), and autopsy-proven focal infarcts in a third patient (fig. 3).

Both patients with sickle-C disease presented with left upper quadrant pain. A 15-year-old boy had CT findings compatible with acute hemorrhage into an enlarged spleen. He was managed conservatively, but returned 3 months later with an acute abdomen and CT findings that indicated a ruptured spleen (fig. 5), confirmed at surgery. A 49-year-old woman had a 3 year history of chronic intermittent left upper quadrant pain. CT showed marked splenomegaly compressing the left kidney, with no focal splenic abnormality. Extensive workup was otherwise negative for etiology of her symptoms. A 36-year-old man with sickle cell trait was admitted with epigastric pain presumed to be pancreatitis and underwent CT to rule out pseudocyst. CT showed a central splenic hematoma and no pseudocyst (fig. 6). The resected spleen was found to have multiple lacerations with both fresh and organizing hemorrhage and many fibrous scars with hemosi-

Downloaded from www.ajronline.org by 65.21.193.86 on 02/24/22 from IP address 65.21.193.86. Copyright ARRS. For personal use only; all rights reserved

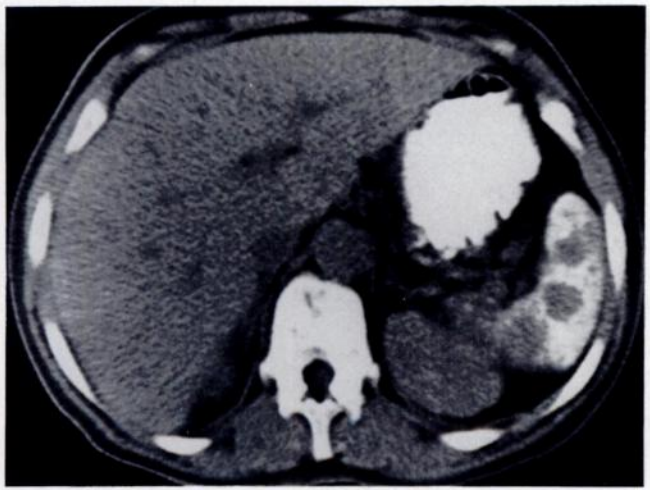

Fig. 4.—54-year-old woman with homozygous disease and 3.4% hemoglobin F who presented with abdominal pain. Spleen is of normal size. There is diffuse calcification of part of spleen with other zones of more normal splenic attenuation. Liver is normal.

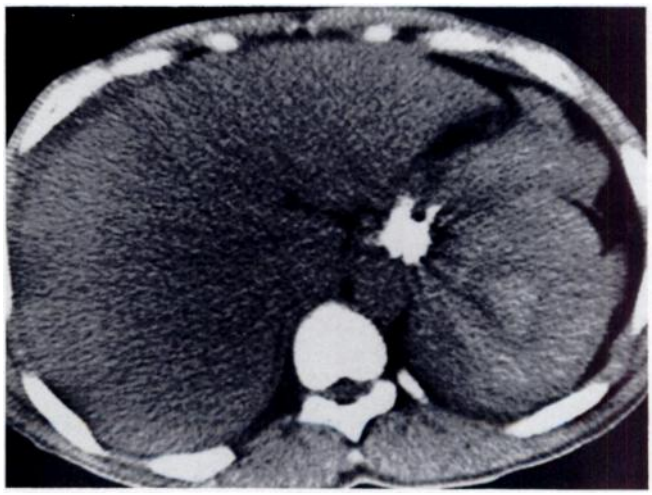

Fig. 6.—36-year-old man with sickle cell trait was a known alcoholic and presented with abdominal pain suggesting pancreatitis. Splenomegaly with area of increased attenuation in spleen centrally was consistent with splenic hemorrhage.

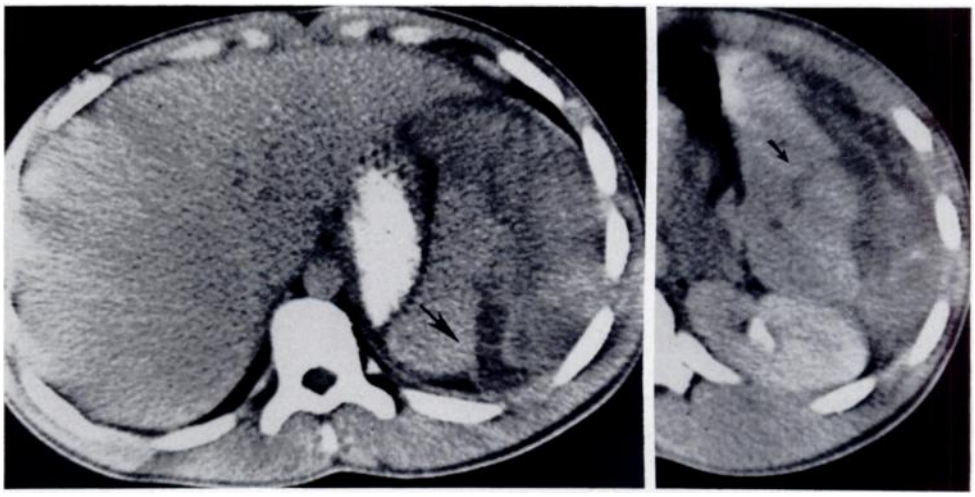

A B

Fig. 5.—15-year-old boy with sickle-C disease who presented with acute left upper quadrant pain. **A**, Marked hepatomegaly with laceration and rupture of spleen (*arrow*). **B**, Through level of kidneys. Enlarged spleen with laceration (*arrow*). Perisplenic fluid is noted laterally near left lateral colic gutter.

derin pigment deposition. No evidence of peripancreatic fluid dissection was appreciated. A 43-year-old woman with sickle-thalassemia had had a total hip replacement 9 days before CT. The postoperative course was complicated by low-grade fever and precipitous 20-point drop to a hematocrit of 6%, attributed initially to a presumed hemolytic reaction to blood transfusion. Clinically the spleen was noted to have enlarged acutely after surgery. At CT a markedly enlarged spleen was seen with patchy areas of increased and decreased attenuation, suggesting both infarction and recent hemorrhage and/or sequestration of red blood cells (fig. 7A). The patient was managed conservatively; abdominal pain resolved over 48 hr, and the hematocrit rose slowly to 20% over the next 3 weeks. A follow-up scan 5 weeks later showed a significant decrease in size with patchy low-density areas compatible with infarcts (fig. 7B).

Discussion

Splenic Findings: Homozygous Sickle Cell Anemia

Unlike normal and most abnormal hemoglobins, deoxygenation of sickle cell hemoglobin produces drastic alterations in the normally pliant erythrocytes' shape and plasticity. The rigid, deformed erythrocytes may become trapped in the small blood vessels, resulting in the so-called "log-jam" occlusion. Chronic anemia, vascular stasis, and vasoocclusion combine to produce the many complications of sickle cell disease [1–4].

Downloaded from www.ajronline.org by 65.21.193.86 on 02/24/22 from IP address 65.21.193.86. Copyright ARRS. For personal use only; all rights reserved

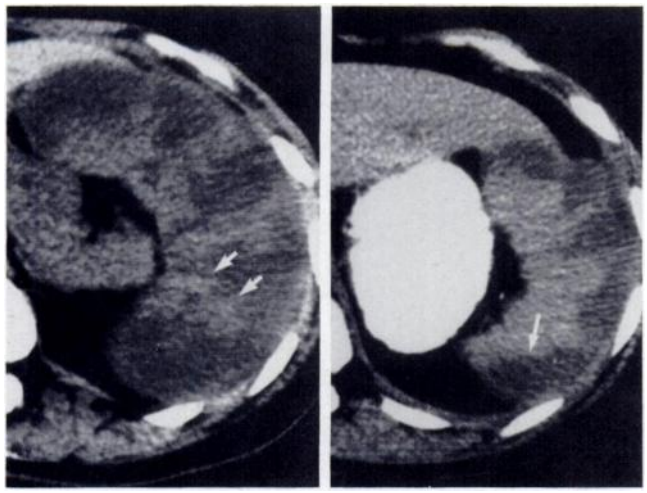

A B

Fig. 7.—43-year-old woman with sickle-thalassemia presented with acute left upper quadrant pain and precipitous hematocrit drop of 20 units. **A**, At level of pancreas. Diffuse splenomegaly. Patchy low densities represent splenic infarction. A few smaller foci of increased density in spleen are consistent with splenic hemorrhage (*arrows*). **B**, 8 weeks later. Decrease in splenic size. Subcapsular fluid collection is consistent with resolving hematoma. Patchy areas of infarction (*arrow*) against background of more normal splenic tissue.

Splenomegaly appears in the first year and parallels both the disappearance of protective fetal hemoglobin F and the onset of declining splenic function. Episodic splenic sequestration may be seen in the first 5 years of life. Vascular occlusion and repetitive local infarction tend to cause the so-called autosplenectomy of the spleen in homozygous disease, with splenic function being lost by age 5. The onset of functional asplenia is reflected by the appearance in the peripheral blood smear of irreversibly sickled cells, anisocytosis, Howell-Jolly bodies, and siderocytes [4]. This early loss of splenic competence in part accounts for the greatly increased risk of infection in the patient with homozygous disease [4–6].

Pathologically, the end-stage spleen is small and fibrotic with marked deposition of hemosiderin and calcium. As early as 1935, Diggs [7] showed microscopic perivascular and parenchymal calcification and increased iron deposition in splenic tissue. Distribution of calcium may be patchy, with scattered focal areas of necrosis that correspond to the low-attenuation areas seen on CT. In one study based on plain supine abdominal radiographs, 31% of homozygous patients were found to have splenic opacification, with an appearance described by some as a "pseudothorotrast" spleen [8]. In our series all homozygous patients were found to have densely calcified spleens; this is due in part to smaller sample size and in part to the greatly increased sensitivity of CT to slight differences of attenuation caused by calcium and iron deposition. Like other calcified soft tissues, such an end-stage spleen can accumulate radionuclide bone agents. Rarely, splenomegaly may persist in a homozygous patient, but such spleens are also nonfunctional, densely fibrotic, and calcified.

While the small and densely calcified spleen of homozygous sickle cell disease is an interesting CT finding, its clinical importance is minimal since in the older child and young adult the spleen has ceased to participate in active disease processes. However, CT also allows imaging of the associated, occasionally unsuspected complications of homozygous disease in the patient with pain and/or fever of uncertain origin. As in our patients, bony sclerosis secondary to infarcts, osteomyelitis, diffuse and focal renal disease, basilar pulmonary abnormalities including infiltrates, infarction, and abscess, and a wide range of hepatic disease may all be noted on abdominal CT.

Hepatic Abnormalities: Homozygous Sickle Cell Anemia

The homozygous patient may be prone to a number of diffuse and focal hepatic abnormalities. By age 6 or 7, originally exuberant mediastinal and tonsillar lymphoid tissue regresses and the spleen has become small and fibrotic, but hepatomegaly tends to persist into adulthood. This may be due at least in part to expansion of the hepatic reticuloendothelial system in response to the increased load created by hemolytic anemia and by autosplenectomy. Vasoocclusion and vascular stasis in the hepatic sinusoids can produce infarction and focal necrosis of hepatic parenchyma. With time, diffuse hepatic damage can result in cirrhosis. The iron load imposed by phagocytosis of red blood cell fragments and by multiple blood transfusions may result in an iron overload state or acquired hemochromatosis [2, 9]. Impairment of the immune response and local conditions of ischemia, biliary stasis, and necrosis predispose to superinfection and can result in hepatic abscess.

CT can be used to delineate abnormalities of hepatic size and to localize and characterize focal lesions. Many of these patients have had prior cholecystectomy and biliary tract surgery, and reflux of air from the duodenum into the biliary tree may be seen, as in one of our patients. Low-density abscesses frequently may be distinguished from infarction by these lesions' characteristic shapes [10], and occasionally by the presence of air within the lesion. Incidental liver cysts may be distinguished by their water density, lower than either infarction or infection.

Sickle Cell Trait

Although at one time it was believed that heterozygous sickle cell trait patients were asymptomatic, it is now recognized that there is a significant morbidity associated with this disease [1–3, 9]. As a rule, however, sickling is elicited only under conditions of extreme stress (flight in unpressurized aircraft, marathon running) [2, 3, 11–13]. Trait patients tend to have far milder disease, with fewer episodes of crisis and infection than their homozygous counterparts. With fewer and less severe episodes of vasoocclusion, the spleen is damaged but not functionally destroyed. Unlike the autosplenectomized organ of the homozygous patient, the sickle-cell-trait spleen continues to provide a site of potential pathology, including splenic abscess, infarcts, and, as in our patient, hemorrhage and rupture.

Sickle Cell–Hemoglobin C Disease

Three per cent of the black population in this country are believed to be carriers of the hemoglobin-C gene, and sickle-

Downloaded from www.ajronline.org by 65.21.193.86 on 02/24/22 from IP address 65.21.193.86. Copyright ARRS. For personal use only; all rights reserved

C disease is about one-fourth as common as homozygous sickle cell disease [1, 2]. Clinically, patients may range from being asymptomatic to having severe disease; one-half become symptomatic in childhood, with the rest tending to present by young adulthood [1–3]. The severity of disease is usually greater than that of trait but less than that of homozygous patients; complications such as painful vasoocclusive crisis, avascular necrosis, and pulmonary infarction or infection are not rare. There are abnormalities of splenic size and function; the risk of infection exceeds normal but does not approach that of the homozygous patient [14, 15]. In comparison with the homozygous patients, both of our sickle-C patients had had relatively mild disease until the time of presentation; one was essentially asymptomatic until 40 years of age. Both patients presented complaining of left upper quadrant pain, which in one case could be explained by the infarction and acute hemorrhage that later developed into splenic rupture. There was no history of trauma in this patient. Large infarctions, pathologic or intentional, may necrose before they can fibrose, leaving the spleen mechanically weakened and at risk for rupture, as in this patient. Spontaneous splenic rupture has been reported after interventional splenic embolization and infarction of enlarged spleens [16].

In the other patient, no satisfactory source of pain was ever defined; it is of interest that such vague left upper quadrant pain has been reported in sickle-C patients as well as in other heterozygous sickle cell states. In many of these cases, however, this pain is attributed to splenic infarction [11, 12, 17]. In this patient with no such focal splenic abnormalities, it may be that marked splenomegaly alone—stretching and distorting the splenic capsule and altering normal anatomic relations to adjacent organs—suffices to explain chronic left upper quadrant symptoms. In such cases, splenectomy terminates symptoms.

Hemoglobin Sickle–Thalassemia Disease

Sickle cell thalassemia patients clinically vary from mild to severe sickle cell disease. Our patient with sickle-thalassemia had had a stormy postoperative course, at least in part attributed to transfusion reaction. However, she developed an acute abdomen with findings referable to the left upper quadrant, and at this time the spleen was noted to have enlarged acutely and to feel "boggy." CT showed patchy areas of altered attenuation suggesting both acute infarction and hemorrhage. Hemolysis alone could account for the patient's remarkable plunge in hematocrit, but the possibility of acute splenic hemorrhage and/or sequestration was raised. Follow-up examination 8 weeks later demonstrated a smaller spleen with patchy low-density areas compatible with resolving infarction and chronic hemorrhage.

Role of CT

The spectrum of homozygous and heterozygous sickle cell disease includes conditions of varying clinical severity that have in common abnormalities of the reticuloendothelial system, particularly the spleen. Abdominal CT can be used to detect and define the many complications to which this population is prone. Homozygous patients tend to have small, densely calcified spleens, of more interest radiographically than clinically. However, these patients have an unusually high incidence of significant hepatic disease. In contrast, the heterozygous population tended to have more normal liver size and liver function tests (reflecting the lesser severity of their hemolytic anemia, the resultant fewer transfusions, and probably the better immunologic status of this group). However, all of these patients had splenomegaly, and three out of four had focal splenic abnormalities as well, including hemorrhage, infarct, rupture, and possible sequestration. It is of interest to note that although sickle cell patients in general and homozygous patients in particular are known to be prone to infection, no cases of splenic abscess were seen in this group. Most likely, this reflects the rarity of splenic abscess in the era of antibiotics, since in the past, sickle cell patients have been disproportionately represented in series of splenic abscesses [18, 19].

REFERENCES

1. Barnhart MI, Henry RL, Lusher JM. *Sickle cell*, Scope publication. Kalamazoo: Upjohn, **1974**
2. Beeson PB, McDermott W, Wyngaarden JB. *Cecil textbook of medicine*, 15th ed, vol 2, section 485. Philadelphia: Saunders, **1979**
3. Williams WJ, Beutler E, Ersler AJ, Rundles RW. *Hematology*. New York: McGraw-Hill, **1977**
4. Powers DR. Natural history of sickle cell disease—the first ten years. *Semin Hematol* **1975**;12:267–285
5. Barrett-Connor E. Bacterial infection and sickle cell anemia. *Medicine* (Baltimore) **1971**;50:97–112
6. Overturf G, Powers D. Multi-institutional study group of pneumoccal vaccine in sickle cell disease: infections in sickle cell anemia: pathogenesis and control. *Tex Rep Biol Med* **1980**;40:283–292
7. Diggs LW. Siderofibrosis of the spleen in sickle cell anaemia. *JAMA* **1935**;104:538–541
8. McCall IW, Vaidya S, Serjeant GR. Splenic opacification in homozygous sickle cell disease. *Clin Radiol* **1981**;32:611–615
9. Behrman RE, Vaughn VC III. *Nelson textbook of pediatrics*, 12th ed, chap 14. Philadelphia: Saunders, **1983**
10. Adler DD, Glazer GM, Silver TM. Computed tomography of liver infarction. *AJR* **1984**;142:315–318
11. King DT, Linstrom RR, State D, Hirose FM, Schwartz A. Unusual cause of acute abdomen: sickle cell trait and nonhypoxic splenic infarction. *JAMA* **1977**;238:2173–2174
12. O'Brien RT, Pearson HA, Godley JA, Spencer RP. Splenic infarction and sickle-(cell) trait. *N Engl J Med* **1972**;287:270
13. Smears DA. The morbidity of sickle cell trait. A review of the literature. *Am J Med* **1978**;64:1021
14. Buchanan GR, Smith SJ, Holtkamp CA, Fuseler JP. Bacterial infection and splenic reticuloendothelial function in children with hemoglobin SC disease. *Pediatrics* **1983**;72:93–98
15. Topley JM, Cupidore L, Vaidya S, Hayes RJ, Serjeant GR. Pneumococcal and other infections in children with sickle cell–hemoglobin C (SC) disease. *J Pediatr* **1982**;10:174–179
16. Wholey MH, Chamarro HA, Rao G, Chapman W. Splenic infarction and spontaneous rupture of the spleen after therapeutic embolization. *Cardiovasc Intervent Radiol* **1978**;1:249–253
17. Yeung K-Y, Lessin LS. Splenic infarction in sickle cell-hemoglobin C disease. *Arch Intern Med* **1976**;136:905–911
18. Lawhorne TW, Zuidema GD. Splenic abscess. *Surgery* **1976**;79:686–689
19. Simson JN. Solitary abscess of the spleen. *Br J Surg* **1980**;67:106–110